

# VEGF, HIF-1 $\alpha$ , and Metabolic Indicators in Esophageal Squamous Cell Carcinoma

Yangyan Chen\*

Shanghai Zhangjiang Institute of Medical Innovation, Shanghai 201204, China

\*Corresponding author: Yangyan Chen, chenyangyan6@126.com

**Copyright:** © 2024 Author (s). This is an open-access article distributed under the terms of the Creative Commons Attribution License (CC BY 4.0), permitting distribution and reproduction in any medium, provided the original work is cited.

**Abstract:** *Objective:* To explore and analyze the expression and clinical significance of vascular endothelial growth factor (VEGF), hypoxia-inducible factor 1 $\alpha$  (HIF-1 $\alpha$ ), and metabolic indicators in esophageal squamous cell carcinoma (ESCC). *Methods:* Sixty ESCC patients admitted to the hospital from October 2021 to October 2023 were selected as the ESCC group. Sixty normal healthy patients from the same period were chosen as the control group. Their serum samples and tissue samples were collected. Metabolic indicators of all study subjects were obtained based on the basic biochemical results upon admission. RT-PCR was utilized to detect the expression of VEGF and HIF-1 $\alpha$  in ESCC tissues. *Results:* The expression of VEGF and HIF-1 $\alpha$  in the ESCC T3+T4 group was significantly higher than that of the carcinoma *in situ* (Tis) group, T1+T2 group, and control group. Furthermore, the expression of HIF-1 $\alpha$  was found to be related to the expression of VEGF, showing a significant correlation between the quantities. Significant differences in the levels of metabolic indicators were observed between the ESCC group and the control group ( $P < 0.05$ ). *Conclusion:* Metabolic indicators are associated with the onset of ESCC in patients. Abnormal lipid metabolism plays a crucial role in the occurrence and development of tumors. The expression of VEGF and HIF-1 $\alpha$  in ESCC tissues significantly correlates with the tumor stage, providing a new reference for the diagnosis and treatment of ESCC.

**Keywords:** VEGF; HIF-1 $\alpha$ ; Metabolic index; Esophageal squamous cell carcinoma (ESCC)

**Online publication:** March 28, 2024

## 1. Introduction

Esophageal squamous cell carcinoma (ESCC) is a malignant tumor of the esophagus caused by esophageal squamous epithelial dysplasia. It represents a common disease, yet its primary cause remains incompletely understood, possibly attributed to factors such as diet, lifestyle, genetics, infection, and other diseases. The clinical presentation typically involves symptoms such as dysphagia, pain, regurgitation, hoarseness, and weight loss, often leading to complications such as infection, fluid imbalance, and psychological disorders<sup>[1]</sup>. Tumor markers play a crucial role in clinical examinations, providing essential guidance for the detection, diagnosis, treatment, and prognosis of diseases, including esophageal cancer. Most clinically detected tumor markers manifest in malignant tumors, benign tumors, embryonic tissues, and even normal tissues. Studies have highlighted the

significance of elevated vascular endothelial growth factor (VEGF) expression as an indicator of poor prognosis in esophageal cancer [2].

Hypoxia-inducible factor 1 $\alpha$  (HIF-1 $\alpha$ ) is a component of HIF-1 that exhibits widespread expression in tissue cells during hypoxia, including the kidney, liver, lung, brain, heart, and various cell lines [3]. Hypoxia represents the most common physiological response of the body. HIF-1 $\alpha$  plays a pivotal role in ischemic-hypoxic brain injury, hypoxic lung disease, ischemic-hypoxic myocardial disease, tumors, and inflammation. Consequently, dynamic monitoring of tumor markers and comprehensive serum index examinations hold greater value [4]. This study focuses on 60 ESCC patients treated at the hospital from October 2021 to October 2023, aiming to explore the expression and clinical significance of VEGF, HIF-1 $\alpha$ , and metabolic indicators in ESCC.

## 2. Materials and methods

### 2.1. General information

Sixty ESCC patients admitted to the hospital between October 2021 and October 2023 were selected as the ESCC group, from whom serum and tissue samples were collected. Among them, there were 39 males and 21 females, with an average age of  $62.76 \pm 4.08$  years. This group comprised 12 cases of carcinoma *in situ* (Tis), 32 cases of T1+T2 stage, and 16 cases of T3+T4 stage. Additionally, 60 normal healthy patients from the same period were chosen as the control group. Basic information such as age and gender was comparable across the four groups, with no significant differences noted ( $P > 0.05$ ). This study was approved by the local ethics committee.

### 2.2. Methods

Fasting blood glucose (FBG), triglycerides (TG), total cholesterol (TC), low-density lipoprotein (LDL), high-density lipoprotein (HDL), and blood uric acid (BUA) levels were obtained for all subjects based on the basic biochemical results upon admission. Additionally, albumin (ALB) was included as a key metabolic indicator for statistical analysis. The expression of VEGF and HIF-1 $\alpha$  in ESCC tissues was detected using real-time polymerase chain reaction (RT-PCR). Mouse anti-human HIF-1 $\alpha$  monoclonal antibody, rabbit anti-human VEGF monoclonal antibody, and immunoassay kits were procured from Beijing Kerimei Technology Co., Ltd., and strictly followed the instructions provided with the kits.

### 2.3. Observation indicators

Metabolic indicators and the expression of VEGF and HIF-1 $\alpha$  in ESCC tissue were analyzed to investigate their clinical significance in ESCC.

### 2.4. Statistical analysis

SPSS 26.0 statistical software was utilized for analysis. Measurement data were expressed as mean  $\pm$  standard deviation (SD). The *t*-test was employed, and the correlation analysis of VEGF and HIF-1 $\alpha$  expression was conducted using Spearman rank correlation analysis. A significance level of  $P < 0.05$  indicated statistical significance.

## 3. Results

### 3.1. Comparison of metabolic index levels between the two groups

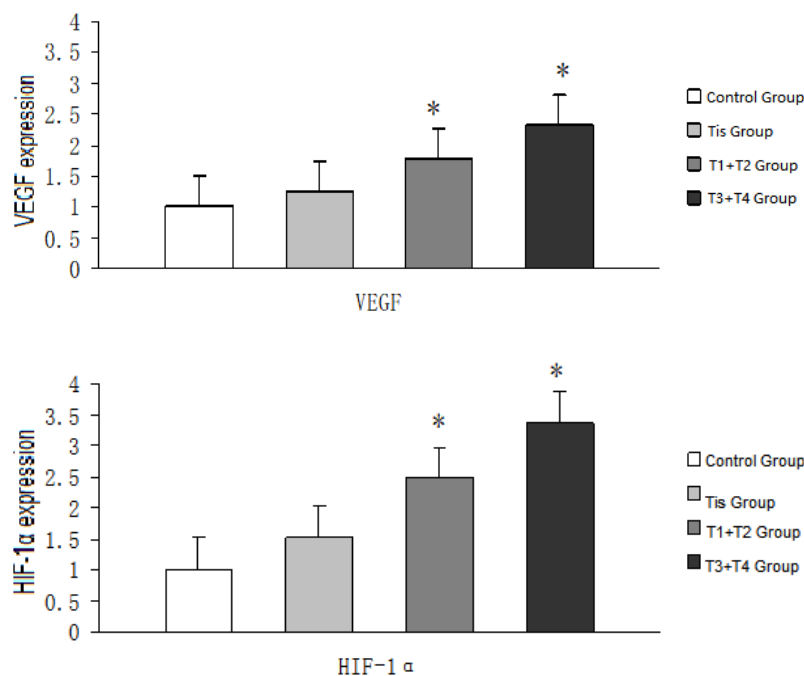
**Table 1** shows that there were significant differences in the levels of metabolic indicators TC, HDL, LDL, and ALB between the ESCC group and the control group. Patients in the esophageal squamous cell carcinoma group had higher TC ( $3.76 \pm 1.24$  mmol/L) and LDL ( $2.98 \pm 0.75$  mmol/L) as compared to the control group of  $3.46 \pm 1.12$  mmol/L TC and  $2.33 \pm 0.97$  mmol/L LDL ( $P < 0.05$ ). The ESCC group also exhibited lower HDL ( $0.76 \pm 0.23$  mmol/L) and ALB ( $32.86 \pm 4.53$  g/L) as compared to the control group of  $1.12 \pm 0.21$  mmol/L HDL and  $39.25 \pm 2.83$  g/L ALB ( $P < 0.05$ ).

**Table 1.** Comparison of metabolic index levels between the two groups

Indicator	Control group (n = 60)	ESCC group (n = 60)	t value	P value
FBG (mmol/L)	$5.82 \pm 4.35$	$5.37 \pm 2.46$	2.863	0.285
TG (mmol/L)	$0.62 \pm 0.45$	$0.53 \pm 0.31$	1.924	0.369
TC (mmol/L)	$3.46 \pm 1.12$	$3.76 \pm 1.24$	8.935	0.003
LDL (mmol/L)	$2.33 \pm 0.97$	$2.98 \pm 0.75$	10.427	0.000
HDL (mmol/L)	$1.12 \pm 0.21$	$0.76 \pm 0.23$	15.982	0.000
BUA ( $\mu$ mol/L)	$310.26 \pm 54.37$	$342.15 \pm 60.94$	1.025	0.682
ALB (g/L)	$39.25 \pm 2.83$	$32.86 \pm 4.53$	8.058	0.005

### 3.2. Comparison of the expression of VEGF and HIF-1 $\alpha$ between the two groups

As shown in **Figure 1**, VEGF and HIF-1 $\alpha$  in the ESCC T3+T4 group were significantly higher than that in the carcinoma *in situ* (Tis) group, T1+T2 group, and control group. There is a significant correlation between VEGF expression and HIF-1 $\alpha$  expression ( $P < 0.05$ ).



**Figure 1.** Comparison of the expression of VEGF and HIF-1 $\alpha$  between the two groups. \* $P < 0.05$

## 4. Discussion

ESCC ranks among the most common malignant tumors of the digestive tract, characterized by complex and diverse mechanisms driving its occurrence and progression. Often detected in advanced stages with high metastatic potential, its prognosis remains poor<sup>[5,6]</sup>. Diagnosis typically involves various modalities such as endoscopy, imaging studies, and laboratory tests. Notably, nodular or cauliflower-like tumors are observed in middle to late stages via endoscopy, along with ulcers and esophageal lumen stenosis. Chromoendoscopy enhances the detection rate of early ESCC<sup>[7]</sup>. Additionally, endoscopic ultrasonography can display changes in the esophageal wall's hierarchical structure, the cancer's infiltration depth, and its relationship with surrounding tissues. CT examination can clarify the staging of esophageal squamous cell carcinoma and can also be used to judge prognosis. PET-CT scans provide valuable insights into primary tumor extent, lymph node involvement, metastasis, and tumor staging<sup>[8-10]</sup>. Laboratory investigations, including blood and urine analyses, liver and kidney function tests, and tumor marker assessments, play pivotal roles in evaluating patients' overall condition and aiding in ESCC diagnosis. Serum tumor markers, renowned for their convenience, minimal invasiveness, and prompt disease status reflection, are widely employed in diagnosing, evaluating treatment efficacy, and assessing prognosis across various cancers<sup>[11,12]</sup>. In clinical practice, combining multiple tumor markers enhances diagnostic sensitivity, compensating for individual marker limitations and enabling early detection and intervention.

ESCC is frequently diagnosed at intermediate to advanced stages. Early screening and prompt identification of suspicious or asymptomatic individuals are pivotal for improving survival rates and prolonging patient survival. Notably, VEGF exhibits elevated production during the transition of ESCC to solid tumors, particularly evident in the Tis and T1 stages, making it a prime candidate for tumor screening using existing clinical methods. Other tumor markers are mostly produced in the T3 and T4 stages of ESCC and are of little significance for early screening<sup>[13]</sup>. VEGF's role in promoting tumor angiogenesis is well-established, with implications for tumor growth and metastasis. Moreover, studies have implicated VEGF in mediating vascular permeability, enhancing malignant extravasation, and facilitating endothelial progenitor cell mobilization to foster tumor neovascularization<sup>[14]</sup>. Targeting VEGF pathways holds promise for novel therapeutic strategies. Hypoxia, a hallmark of aggressive tumors, underscores the importance of investigating new HIF-1 $\alpha$  target genes to develop targeted therapies that impede disease progression. Additionally, hypoxia within the tumor microenvironment triggers inflammatory responses, further exacerbating tumorigenesis, with HIF-1 $\alpha$  potentially mediating inflammatory effects<sup>[15,16]</sup>. This study reveals significantly elevated expression levels of VEGF and HIF-1 $\alpha$  in the ESCC T3+T4 group compared to the Tis and T1+T2 groups, with a notable correlation between HIF-1 $\alpha$  and VEGF expression levels. This highlights the prognostic and therapeutic relevance of heightened VEGF and HIF-1 $\alpha$  expression levels. Elevated tumor marker levels are implicated in tumor initiation and progression.

This study's findings demonstrate significant differences in metabolic indicator levels, including TC, HDL, LDL, and ALB, between the ESCC and control groups. Specifically, ESCC patients exhibited high TC ( $3.76 \pm 1.24$  mmol/L) and LDL ( $2.98 \pm 0.75$  mmol/L) levels but lower HDL ( $0.76 \pm 0.23$  mmol/L) and ALB ( $32.86 \pm 2.83$  g/L) compared to the control group (TC:  $3.46 \pm 1.12$  mmol/L; LDL:  $2.33 \pm 0.97$  mmol/L; HDL:  $1.12 \pm 0.21$  mmol/L; ALB:  $39.25 \pm 2.83$  g/L). These metabolic changes influence ESCC progression, with proliferating carcinoma cells driving increased cholesterol demand and LDL serving as a key cholesterol transporter, contributing to elevated levels. Conversely, HDL primarily facilitates cholesterol transport to the liver for degradation, hence its decreased levels in ESCC patients. Consequently, abnormal lipid metabolism plays a pivotal role in tumor development. The significant correlation between VEGF and HIF-1 $\alpha$  expression and tumor stage underscores their potential as diagnostic and therapeutic targets for ESCC.

## Disclosure statement

The author declares no conflict of interest.

## References

- [1] Li X, Yang J, Wang J, 2020, Research Status of Genomics, Proteomics, and Metabolomics Application in Esophageal Cancer Screening and Early Diagnosis. *Chinese Journal of Cancer Prevention and Treatment*, 27(6): 493–498.
- [2] Cui Y, Chen H, Xi R, et al., 2022, Whole-Genome Sequencing of 508 Patients Identifies Key Molecular Features Associated with Poor Prognosis in Esophageal Squamous Cell Carcinoma. *Cell Res*, 30(10): 902–913. <https://doi.org/10.1038/s41422-020-0333-6>
- [3] Wan P, Shen W, Peng Z, et al., 2022, Characteristic Intestinal Flora and Associated Biomarkers in Esophageal Cancer Based on PacBio SMRT Sequencing. *Journal of Environmental and Occupational Medicine*, 39(9): 1011–1020. <https://doi.org/10.11836/JEOM22065>
- [4] Yang L, Miao Z, Kang X, 2023, Changes and Clinical Significance of Peripheral Serum VEGF Before and After Chemotherapy in Patients with Esophageal Squamous Cell Carcinoma. *Hebei Medicine*, 45(21): 3226–3229.
- [5] Liu Z, Zhao Y, Kong P, et al., 2023, Integrated Multi-Omics Profiling Yields a Clinically Relevant Molecular Classification for Esophageal Squamous Cell Carcinoma. *Cancer Cell*, 41(1): 181–195.e9. <https://doi.org/10.1016/j.ccell.2022.12.004>
- [6] Tang L, Liu T, Jia X, et al., 2022, Effect and Prognosis Analysis of Intensity-Modulated Radiotherapy Combined with Concurrent CF Regimen on IGF-1 and VEGF in Esophageal Squamous Cell Carcinoma. *Zhongnan Journal of Medical Sciences*, 50(2): 245–248.
- [7] Chen X, Yu L, Zhou J, et al., 2023, Inhibition of p62 and/or NFE2L2 Induced Autophagy Impaired Esophageal Squamous Cell Cancer Metastasis by Reversing EMT. *Gene*, 858: 147194. <https://doi.org/10.1016/j.gene.2023.147194>
- [8] Guo J, Alimujiang M, Idelis A, et al., 2023, The Role and Changes of Lymphatic Vessels and Endothelial Cells in Esophageal Cancer's Lymphatic Metastasis. *Chinese Clinic of Thoracic and Cardiovascular Surgery Magazine*, 30(5): 766–772.
- [9] Chen D, Di Y, 2021, The Influence of Blood Lipid Levels and Metabolic Indicators on the Incidence of Esophageal Cancer. *Modern Oncology*, 29(21): 3770–3772.
- [10] Wang X, Yang H, Fan J, et al., 2023, Exploration of Esophageal Squamous Cell Carcinoma Metabolomic Markers Based on the Lin County Nutritional Intervention Trial Population. *Chinese Oncology*, 32(2): 154–160.
- [11] Li Y, Xing S, Chen F, et al., 2023, Intracellular *Fusobacterium nucleatum* Infection Attenuates Antitumor Immunity in Esophageal Squamous Cell Carcinoma. *Nat Commun*, 14(1): 5788. <https://doi.org/10.1038/s41467-023-40987-3>
- [12] Cui S, McGranahan N, Gao J, et al., 2023, Tracking the Evolution of Esophageal Squamous Cell Carcinoma Under Dynamic Immune Selection by Multi-Omics Sequencing. *Nat Commun*, 14(1): 892. <https://doi.org/10.1038/s41467-023-36558-1>
- [13] Cao Z, Yang J, 2023, The Value of Serum SCC-Ag, VEGF, and UHRF1 Levels in Predicting the Recurrence of Esophageal Squamous Cell Carcinoma After Radical Surgery. *Henan Medical Research*, 32(6): 1024–1029.
- [14] Hua Y, He K, Zhang J, et al., 2023, Effects of High Expression of Hypoxia-Inducible Factors and Angiogenic Factors Induced by *Fusobacterium nucleatum* on Survival Prognosis of Patients with Esophageal Squamous Cell Carcinoma. *Journal of Shandong University (Medical Edition)*, 61(11): 59–67.
- [15] Peng M, Zhou X, Jiang L, 2020, Effect of VEGF and HIF-1 $\alpha$  Expression on the Efficacy of Radiotherapy in Patients with Esophageal Squamous Cell Carcinoma. *Journal of Practical Cancer*, 35(10): 1631–1634.
- [16] Liu X, Liu Y, Fan Z, et al., 2022, Expression and Clinical Significance of Hypoxia-Inducible Factor-1 $\alpha$  and Vascular

Endothelial Growth Factor in Esophageal Squamous Cell Carcinoma Tissue. Journal of Xinjiang Medical University, 45(10): 1099–1103.

**Publisher's note**

Bio-Byword Scientific Publishing remains neutral with regard to jurisdictional claims in published maps and institutional affiliations.