

Application of Pelvic Peritoneum Closure Combined with Extraperitoneal Colostomy in Laparoscopic Surgery for Low Rectal Cancer

Hongliang Yao, Jipan Liu, Caihua Sun, Chengjun Wang, Yun Li, Li Li, Bin Zhao, Jia Liu*

The Second Department of General Surgery, Hengshui People's Hospital, Hengshui 053000, Hebei Province, China

*Corresponding author: Jia Liu, liujia01@hotmail.com

Copyright: © 2023 Author(s). This is an open-access article distributed under the terms of the Creative Commons Attribution License (CC BY 4.0), permitting distribution and reproduction in any medium, provided the original work is cited.

Abstract: *Background:* In the treatment of colorectal cancer, laparoscopic surgery has seen a significant amount of success. Reducing the risk of postoperative complications and improving patients' quality of life can be accomplished by appropriately employing pelvic peritoneal repair and sigmoid colostomy when appropriate. *Objective:* To compare fusion closure of pelvic peritoneum combined with extraperitoneal colostomy with non-closure of pelvic peritoneum combined with intraperitoneal colostomy in patients with low rectal cancer who had permanent colostomy. *Methods:* Low rectal cancer patients admitted to Hengshui People's Hospital for permanent colostomy were evaluated. The participants were divided into two groups: an observation and a control group. All 30 cases in the observation group underwent pelvic peritoneum closure and extraperitoneal colostomy, while the other 30 cases in the control group underwent intraperitoneal colostomy. The C-reactive protein (CRP) levels of the participants in both groups were evaluated for 6 months to 2 years (24 h before, 24 h after, 48 h after, 96 h after surgery). *Results:* Comparing the colostomy operative time, time to first passage of flatus postoperatively, time to first defecation postoperatively, length of hospital stay, laboratory indicators, stoma-related complications, colostomy function, etc., the colostomy operative time significantly differed between the two groups ($P < 0.05$); the observation group did considerably better than the control group in terms of stoma-related complications and bowel movement control 6 months after surgery ($P < 0.05$); and although serum CRP levels increased in both groups 48 h after surgery, the difference was significant ($P < 0.05$). *Conclusion:* Extraperitoneal colostomy can improve the quality of life of patients with permanent stoma and reduce the occurrence of stoma-related complications. Thus, this technique is worthy of promotion in clinical practice.

Keywords: Low rectal cancer; Closure of pelvic peritoneum; Permanent colostomy; Extraperitoneal colostomy via rectus abdominis

Online publication: May 29, 2023

1. Background

Colorectal cancer is one of the common malignant tumors of the intestines in China. In terms of the incidence rate and mortality rate, colorectal cancer is the third most common malignant tumor and fourth deadliest cancer worldwide. This cancer not only affects the patient's health, but also places a significant financial burden on the patient. The continuous deepening of cancer research and improvement of diagnosis and treatment have significantly improved the five-year survival rate of patients with colorectal cancer. In China, the incidence of colorectal cancer is increasing every year^[1,2]. The persistent development of medical standards enables early detection, diagnosis, and treatment of colorectal cancer, all of which can help improve the quality of life of patients. In China, middle and low rectal cancers have higher incidence

rates. Unfortunately, since middle and low rectal cancers are not easily detected and diagnosed in time, permanent colostomy is required in some patients whose anus cannot be preserved during surgical treatment. As colorectal cancer research deepens, complete surgical treatment options are used. Colorectal cancer surgery has evolved from open to laparoscopic to robotic. Laparoscopic approach has become the standard surgical procedure for colorectal cancer surgery due to its minimal invasiveness, clear vision, and finer dissection [3-5]. The reasonable use of pelvic peritoneal reconstruction and sigmoid colostomy can help reduce postoperative complications and improve the quality of life of patients. However, surgical treatment will inevitably result in some complications [6]. Standardized and improved surgical procedures can reduce complications and improve patients' quality of life. In the present study, we compared 60 patients with low rectal cancer admitted to Hengshui People's Hospital from January 2019 to January 2021 for surgery. The aim of this study was to compare the advantages and disadvantages of pelvic peritoneum closure and colostomy, as well as to follow-up to observe the bowel movement control in the patients with colostomy. We performed pelvic peritoneum closure combined with extraperitoneal colostomy under laparoscopic surgery for low rectal cancer to evaluate its benefits and improve the patients' quality of life. This study provides guidance for future clinical work and to improve the quality of life of patients after surgery.

2. Materials and methods

2.1. Baseline information

We selected 60 patients with low rectal cancer (tumor < 5 cm from the anus) who were admitted to the Department of General Surgery of Hengshui People's Hospital from January 2019 to January 2021. These patients were diagnosed with rectal adenocarcinoma via pathological examination, and all of them underwent laparoscopic Miles' surgery (abdominoperineal resection combined with rectal cancer resection). According to the type of surgical method used, the patients were divided into two groups: an observation group and a control group. The observation group composed of 30 cases who were treated with pelvic peritoneum closure combined with tunnel colostomy via rectus abdominis. There were 18 male and 12 female patients, age ranging from 26 to 68 years, with an average age of 48.6 ± 6.24 years. In terms of postoperative pathological examination and staging, there were 22 cases with tumor diameter less than 5 cm, 17 cases with TNM stage I-II, and 13 cases with TNM stage III-IV. The control group composed of 30 cases who were treated with non-closure of pelvic peritoneum combined with intraperitoneal colostomy. The control group consisted of 14 male and 16 female patients, age ranging from 25 to 69 years, with an average age of 43.6 ± 5.68 years. In terms of postoperative pathological examination and staging, there were 18 cases with tumor diameter < 5 cm, 16 cases with TNM stage I-II, and 14 cases with TNM stage III-IV. There was no significant difference in the baseline parameters between the two groups ($P > 0.05$). This study was approved by the medical ethics committee of Hengshui People's Hospital (Approval No. 2020-2-007). Informed consent was obtained from the patients and their family members before being recruited for this study.

2.2. Methods

Both groups of patients received general anesthesia, and their heads were positioned lower than their feet. Dissociation, specimen removal, and perineum suture were the same. The surgery followed total mesorectal excision (TME). In the observation group, pelvic peritoneum closure was paired with extraperitoneal colostomy via rectus abdominis, whereas in the control group, intraperitoneal colostomy was employed. The sacrum was drained in both groups. After suturing the perineal incision, 2-0 barbed suture (Johnson & Johnson SAPP1A405) was used with 1 cm stitches and a 0.5 cm margin. The pelvic peritoneum was sutured continuously from the bladder or uterine rectal lacuna to the pelvic entry above the iliac crest without producing pores. In the lateral sigmoid colon extraperitoneum, forceps were used to bluntly detach the

extraperitoneal space from the lateral abdominal wall to produce an extraperitoneal tunnel. Extraperitoneal colostomy was performed via rectus abdominis. The patient circumstances influenced the preoperative positioning. The navel and left anterior superior iliac spine make up around 1/3 to 1/2 of the flat abdominal wall. A 2–3-cm circular incision was performed to remove the skin and subcutaneous fat to reveal the anterior rectus sheath and rectus abdominis (blunt dissection to protect the integrity of muscle fibers). Dissection was made from the posterior rectus sheath to the peritoneum. The peritoneum on the side of the blunt tunnel separation outside the peritoneum would merge with the peritoneum on the side of the intestinal tube exiting the stoma. The tunnel's width was modified based on the intestine and mesentery, and the sigmoid colon was led out along the tunnel to avoid twisting or folding of the mesentery. There was moderate intestinal tube tension near the stoma. The intestinal stoma was sutured with the rectus abdominis anterior sheath, subcutaneous tissue, and dermis, and an ostomy bag was externally fixed. Intraperitoneal colostomy via rectus abdominis was performed. The navel and the left anterior superior iliac spine 1/3 to 2/3 of the abdominal wall were selected as the fistula location, and layer-by-layer dissection was used to expose the peritoneum. Given a tight sigmoid colon, the intestine and abdominal wall were repaired in layers (**Figure 1**).

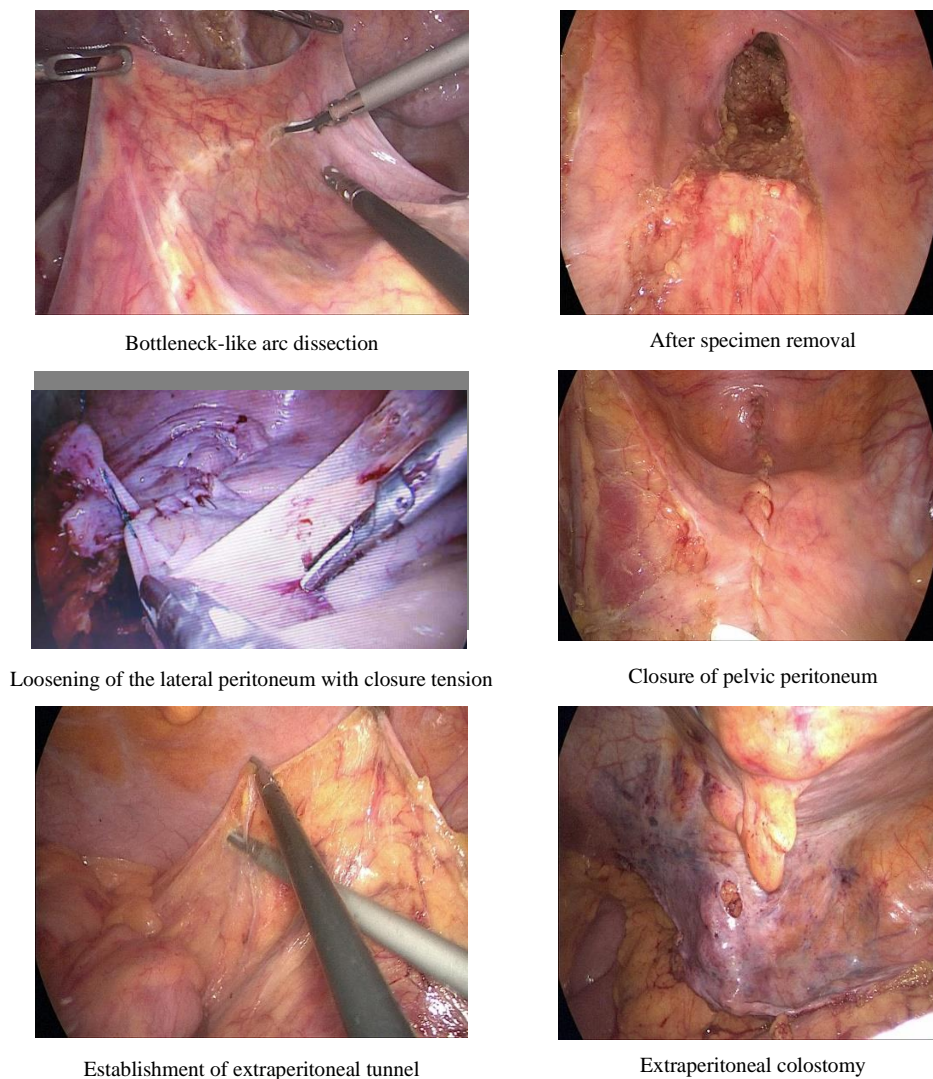


Figure 1. Dissociation, specimen removal, and perineum suture. The surgery followed total mesorectal excision (TME). In the observation group, pelvic peritoneum closure was paired with extraperitoneal colostomy via rectus abdominis, while in the control group, intraperitoneal colostomy was employed.

2.3. Observation indicators

- (1) Surgery-related indicators: colostomy operative time, time to first passage of flatus postoperatively, time to first defecation postoperatively, and length of hospital stay.
- (2) Laboratory indicators: serum C-reactive protein (CRP) levels 24 h before operation and 24 h, 48 h, and 96 h after surgery; the CRP levels were determined using the turbidimetric method (normal reference value 0–8 mg/L; reagents were purchased from Goldsite Co., Ltd., Shenzhen, China).
- (3) Follow-up indicators: stoma-related complications (stoma bleeding, stoma separation, dermatitis around the stoma, stoma stenosis, stoma retraction, stoma prolapse, intestinal obstruction, and parastomal hernia) were evaluated for at least 6 months to 2 years (through follow-up visits, telephone follow-up, WeChat follow-up, *etc.*); bowel movement control was evaluated by interviewing the patients about their bowel movement control ability and any signals (abdominal distension, bowel sounds, and peristalsis of the left lower abdominal wall) before defecation at 2 months, 4 months, and 6 months after surgery; stoma function was evaluated based on three aspects: (i) whether the patients can detect defecation signals before bowel movement, (ii) whether the patients can distinguish flatus from feces, and (iii) whether the patients can perceive the whole process of defecation.

2.4. Statistical analysis

Statistical Package for Social Sciences (SPSS) version 21.0 was used to analyze and process all data. Measurement data were expressed in mean \pm standard deviation (SD) and analyzed using *t* test. Count data were expressed in percentage (%) and analyzed using chi-square (χ^2) test or Fisher's exact test (when the number of cases was 0 or less than 5). $P < 0.05$ indicates statistically significant difference.

3. Results

3.1. Surgery-related indicators

The colostomy operative time was significantly different between the observation group and the control group ($P < 0.05$). There were no significant differences in the time to first flatus, time to first defecation, and length of hospital stay ($P > 0.05$), as shown in **Table 1**.

Table 1. Comparison of surgery-related indicators between the observation group and the control group

Group	Colostomy operative time (min)	Time to first flatus (h)	Time to first defecation (h)	Length of hospital stay (days)
Observation group	26.64 \pm 2.45	30.28 \pm 4.38	52.48 \pm 4.78	14.42 \pm 3.68
Control group	24.86 \pm 2.78	29.44 \pm 3.46	53.26 \pm 4.86	15.18 \pm 2.46
<i>t</i>	2.854	0.824	0.627	0.94
<i>P</i>	0.000	0.413	0.553	0.351

3.2. Laboratory indicators

There was no significant difference in serum CRP level between the observation group and the control group at 24 h before surgery, 24 h after surgery, and 96 h after surgery ($P > 0.05$). At 48 h after surgery, the serum CRP levels of the two groups increased, and the difference was statistically significant ($P < 0.05$), as shown in **Table 2**.

Table 2. Comparison of laboratory indicators after colostomy between the two groups

	CRP levels (mg/L)			
	24 h before surgery	24 h after surgery	48 h after surgery	96 h after surgery
Observation group	4.54 ± 0.78	30.78 ± 3.98	47.75 ± 4.38	25.46 ± 6.15
Control group	4.67 ± 0.82	31.52 ± 4.13	53.16 ± 5.19	28.88 ± 7.43
<i>t</i>	0.629	0.708	4.363	1.942
<i>P</i>	0.532	0.482	0.000	0.057

3.3. Stoma-related complications

Based on the analysis of stoma-related complications in the two groups, the patients in the observation group had no parastomal hernias, and the total number of stoma-related complications in the observation group was fewer than that in the control group; there was statistical difference between the two groups ($P < 0.05$). In terms of bleeding, stoma separation, dermatitis around stoma, stoma retraction, stoma stenosis, stoma prolapse, intestinal obstruction, and parastomal hernia, there was no statistical difference between the two groups ($P > 0.05$), as shown in **Table 3**. (Note: There could be one or more stoma-related complications in the same patient, and thus the total complication rate was relatively high.)

Table 3. Comparison of stoma-related complications between the two groups

Group	Stoma bleeding	Stoma separation	Dermatitis around stoma	Stoma retraction	Stoma stenosis	Stoma prolapse	Intestinal obstruction	Parastomal hernia	Total number of complications (%)
A	0	2	4	1	1	0	0	0	8 (24.2%)
B	1	4	4	1	2	2	4	4	22 (73.3%)
χ^2		0.19*	0.14	0.52*	0.00*	0.52	2.41*	2.41*	13.07
<i>P</i>	1.000	0.667	0.704	0.472	1.000	0.472	0.121	0.121	0.000

The blanks indicate Fisher's exact test. *Yates-corrected chi-square test was used. Abbreviations: A, observational group; B, control group.

3.4. Follow-up indicators

After postoperative follow-up for 2 months, 4 months, and 6 months, the patients could detect defecation signals before bowel movement; their stomas were evaluated based on whether they could distinguish flatus from feces as well as perceive the whole process of defecation. The number of cases in the observation group was generally more than that in the control group. The indicators were not significantly different between the timepoints at 2 months after surgery and at 4 months after surgery ($P > 0.05$), but there were statistical differences in the follow-up indicators 6 months after surgery ($P < 0.05$), as shown in **Table 4**.

Table 4. Comparison of stoma function at 2 months, 4 months, and 6 months after surgery

	2 months after surgery		<i>P</i>	4 months after surgery		<i>P</i>	6 months after surgery		<i>P</i>
	Observation	Control		Observation	Control		Observation	Control	
A	6	10	0.243	13	19	0.121	19	26	0.037
B	4	8	0.197	8	15	0.063	15	24	0.015
C	2	5	0.421	6	14	0.028	14	22	0.035

Abbreviations: A, defecation signals before bowel movement; B, ability to distinguish between flatus and feces; C, ability to perceive the whole process of defecation. Observation refers to the observation group, and control refers to the control group.

4. Discussion

At present, whether the pelvic peritoneum should be closed after laparoscopic Miles' surgery in low rectal cancer is still debatable [7-9]. The present study cannot prove the association between pelvic peritoneum reconstruction and the occurrence of postoperative intestinal obstruction. However, 4 cases of intestinal obstruction were observed in the control group whose pelvic peritoneum was unclosed. Among them, one case was examined in a second surgery. Partial small bowel resection was performed in view of severe bowel adhesions to the pelvic group. Hence, we believe that closing the pelvic peritoneum has clinical significance. (2) Some patients with rectal cancer require postoperative radiotherapy due to their condition. If the pelvic floor and peritoneum are not sutured, the small intestine that has herniated into the pelvic floor is prone to radiation enteritis, which may trigger intestinal obstruction. Severe cases require surgical treatment, and subsequent surgeries may be more challenging. The recovery of patients after surgery may be difficult, which increases the physical and mental burden on patients. (3) In many instances after Miles' surgery, infection or even dehiscence of the perineal wound occurs. If the pelvic floor and peritoneum are not sutured, perineal inflammation may occur, causing pelvic infection and small bowel obstruction. Closure of the pelvic peritoneum is a routine operation in Miles' open abdomen surgery. In this study, presacral drainage tube was routinely placed through the perineum to reduce the risk of retrograde infection, and the closure of pelvic peritoneum was performed in this study. The main points of the operation are summarized as follows: (i) taking into account of individual differences, tension was reduced when closing the peritoneum; (ii) TME principle was adhered to during lateral dissection in order to properly retain the lateral peritoneum in preparation for closure [10-13]; when the tension was high and the peritoneum could not be closed, ultrasonic knife gasification was used to dissect the peritoneum and subperitoneal fascia to properly loosen the lateral peritoneum, maintain the continuity of the subperitoneal fascia, and achieve tension-free closure of the pelvic peritoneum; (3) regarding the pelvic floor design, Denonvilliers' fascia was dissected in the avascular area about 0.5 cm above the peritoneal reflex, and 2-0 barbed suture was used to close the pelvic peritoneum from the pelvic floor to the proximal end; the end of the thread was clamped using Hem-o-lok clip. Through the aforementioned methods, pelvic peritoneal reconstruction was successfully completed in all cases of the present study. Based on the findings of this study, there are several advantages of extraperitoneal colostomy of sigmoid colon. (1) Through sigmoid colon extraperitoneal colostomy, the abdominal organ pressure on the abdominal wall is diffused and buffered, and the stoma form is altered. This minimizes the colon-abdominal wall space and parastomal hernia. No patient in the observation group reported parastomal hernia, although the number of cases and follow-up period were found to be associated. Thus, further clinical research is necessary. Similar results have been observed by Tomasz [14]. (2) The intestinal stoma and peritubular tissue may become connected and fixed, supporting and stabilizing the tunnel colon and decreasing retraction or prolapse of the colostomy tube. Peritubular tissue presses on the colostomy tube to improve feces control. (3) The intestinal stoma's parietal peritoneum is nerve-rich. During intestinal expansion caused by gas or feces, nerve terminals in the parietal peritoneum are stimulated, triggering the defecation reflex. This allows patients to detect and control bowel motions, unlike intraperitoneal colostomy. Extraperitoneal colostomy should be every surgeon's first choice, although this approach should be thoroughly assessed based on the patient's condition. The present study's small sample size and short follow-up period are limitations. To compare the long-term consequences of the two colostomy procedures and the function of artificial anus, a large sample study and extended follow-up are needed. This would contribute to finding a better laparoscopic permanent sigmoid colostomy technique to improve patients' quality of life.

Colostomy may cause complications, among which parastomal hernia is a complex problem. Treatment is determined by the size of the inguinal ring and hernia contents. Some patients would require hernia surgery. Foreign body reaction from postoperative patch implantation, along with feces contamination and

infection, causes operation failure and recurrence. In severe cases, intestines may block. The subsequent surgery is more demanding and expensive. Effective methods to decrease parastomal hernia after a permanent colostomy are clinically significant. The incidence rate of parastomal hernia varies ^[15]. In order to reduce the occurrence of parastomal hernia, some surgeons place a patch in the muscle layer of the stoma in advance to prevent the occurrence of parastomal hernia ^[16,17]. However, infection may occur since the patch is a foreign body. In addition, the implanted patch increases the treatment cost. Performing complex operation in laparoscopic surgery is not practical, as it requires surgeons with high technical skills. In theory, extraperitoneal colostomy via rectus abdominis can reduce the incidence of parastomal hernia. In line with results reported in other literature, this study demonstrated that the incidence of parastomal hernia in the extraperitoneal colostomy group was significantly lower than that in the intraperitoneal colostomy group ^[18]. When performing colostomy, it is necessary to ensure that the intestinal tube and its mesentery pass through the preset tunnel anteriorly, without squeezing or twisting. The tension of the colon in the tunnel should be reduced as much as possible to ensure sufficient blood supply to the intestinal stoma and unobstructed intestinal cavity. Therefore, choosing an appropriate colostomy method, upgrading nursing education on stoma, reducing stoma-related complications, and further improving the quality of life of patients after surgery are the issues that clinical surgeons should address and continue to explore. In the present study, we evaluated the patients' CRP levels before and after surgery. A significant rise in CRP suggests acute inflammation or infection, prompting doctors or nurses to take appropriate action. This study suggests that surgical stress and inflammation are behind the increase in postoperative CRP levels, which indicates incision inflammation. After inflammation reduces, CRP returns to normal ^[19].

5. Conclusion

In recent years, laparoscopic surgery for colorectal cancer has become more refined and standardized following the intense development of this technique. Laparoscopic surgery is commonly employed in most of the colorectal cancer surgeries in our hospital. Extraperitoneal colostomy via rectus abdominis is associated with good clinical outcomes in the treatment of low rectal cancer and anal cancer. This colostomy method is used as the routine in laparoscopic Miles' surgery. However, owing to the small number of samples and short follow-up period in the present study, clinical studies involving larger samples are needed for confirmation. Closure of pelvic peritoneum combined with extraperitoneal colostomy via rectus abdominis can reduce postoperative complications and improves the patient's ability to control defecation after the surgery. Therefore, this technique can provide solace to the patients and improve their quality of life. On this basis, this technique is worthy of further improvement and promotion in clinical practice.

Funding

The research work is funded by the Medical Science Research Project of Hebei Province (20211322).

Disclosure statement

The authors declare no conflict of interest.

Author contributions

H.Y. and C.S. contributed in the study conception, as well as the design and writing of the first draft of the manuscript; C.W. and J.L. collected and analyzed the data; Y.L and L.L interpreted the results; and B.Z. and J.L. supervised the whole research and revised the final draft of the manuscript. All authors agreed to be accountable for all aspects of the work.

References

- [1] National Cancer Center, China, Expert Group of the Development of China Guideline for the Screening, Early Detection and Early Treatment of Colorectal Cancer, 2021, Guidelines for Screening, Early Diagnosis and Treatment of Colorectal Cancer in China (2020, Beijing). *Chinese Journal of Oncology*, 43(1): 16–38.
- [2] Wu Z, Deng Y, 2017, The Influence of Differences Between the East and West in Colorectal Cancer Epidemiology on Tumor Location. *Chinese Journal of Oncology Prevention and Treatment*, 9(5): 356–360.
- [3] Expert Group on Chinese Colorectal Cancer Diagnosis and Treatment Standards (2020 Edition), 2020, National Health Commission Chinese Colorectal Cancer Diagnosis and Treatment Standards (2020 Edition). *Chinese Journal of Gastrointestinal Surgery*, 23(6): 521–540.
- [4] Zheng M, Ma J, 2019, Updates of the 2018 Edition of “Laparoscopic Colorectal Cancer Radical Surgery Operation Guidelines”. *Chinese Journal of Surgery*, 57(3): 224–226.
- [5] Lian L, Lan P, 2021, Interpretation of the National Health Commission’s Chinese Colorectal Cancer Diagnosis and Treatment Standards (2020 Edition) – Surgery. *Journal of Clinical Surgery*, 29(1): 10–12.
- [6] Wang G, Hu X, Zhang N, et al., 2021, Prevention and Treatment Strategies for Major Complications After 30 Years of Laparoscopic Rectal Cancer Surgery in China. *Chinese Journal of Operative Procedures of General Surgery*, 15(1): 14–19.
- [7] Rahbari NN, Weitz J, Hohenberger W, et al., 2010, Definition and Grading of Anastomotic Leakage Following Anterior Resection of the Rectum: A Proposal by the International Study Group of Rectal Cancer. *Surgery*, 147(3): 339–351.
- [8] Keller DS, Ibarra S, Flores-Gonzalez JR, et al., 2016, Outcomes for Single Incision Laparoscopic Colectomy Surgery in Obese Patients: A Case-Matched Study. *Surg Endosc*, 30(2): 739–744.
- [9] Wang Y-L, Zhang X, Mao J-J, et al., 2018, Application of Modified Primary Closure of the Pelvic Floor in Laparoscopic Extralevator Abdominal Perineal Excision for Low Rectal Cancer. *World Journal of Gastroenterology*, 2018(30): 3440–3447.
- [10] Li G, Zhao L, 2011, Anatomy Summary of Laparoscopic Radical Resection of Colorectal Cancer. *Chinese Journal of Practical Surgery*, 31(9): 844–848.
- [11] Chi P, Wang X, 2021, Total Mesenterectomy with Partial Denonvilliers’ Fascia: Balance Between Oncology and Function. *Chinese Journal of Digestive Surgery*, 20(1): 78–84.
- [12] Sakr A, Sauri F, Alessa M, et al., 2020, Assessment and Management of Low Anterior Resection Syndrome After Sphincter Preserving Surgery for Rectal Cancer. *Chinese Medical Journal*, 133(15): 1824–1833.
- [13] Faylona JMV, 2018, Invited Comment to: European Hernia Society Guidelines on Prevention and Treatment of Parastomal Hernias. *Hernia: The Journal of Hernias and Abdominal Wall Surgery*, 22(1): 203.
- [14] Zieliński T, Czyżewski P, Szczepkowski M, 2016, The Usefulness of Anorectal Manometry in Patients with a Stoma Before and After Surgery to Restore the Continuity of the Gastrointestinal Tract. *Polski Przegląd Chirurgiczny*, 88(1): 1–6.
- [15] Lian L, Wu XR, He XS, 2012, Extraperitoneal Vs. Intraperitoneal Route for Permanent Colostomy: A Meta-Analysis of 1,071 Patients. *International Journal of Colorectal Disease*, 27(1): 59–64.

- [16] Cross AJ, Buchwald PL, Frizelle FA, et al., 2017, Meta-Analysis of Prophylactic Mesh to Prevent Parastomal Hernia. *The British Journal of Surgery*, 104(3): 179–186.
- [17] Xu B, Zhou L, Duan J, et al., 2021, Meta-Analysis of the Application Value of Preventive Patch Placement in the Prevention of Parastomal Hernia. *Chinese Journal of General Surgery*, 30(4): 386–398.
- [18] Guraya SY, 2015, Association of Type 2 Diabetes Mellitus and the Risk of Colorectal Cancer: A Meta-Analysis and Systematic Review. *World Journal of Gastroenterology*, 21(19): 6026–6031.
- [19] Lee SC, Huh JW, Lee WY, et al., 2020, Prognostic Value of Serum Inflammatory Markers in Colorectal Cancer. *International Journal of Colorectal Disease*, 35(7): 1211–1219.
- [20] Fingren J, Lindholm E, Petersén C, et al., 2018, A Prospective, Explorative Study to Assess Adjustment 1 Year After Ostomy Surgery Among Swedish Patients. *Ostomy/Wound Management*, 64(6): 12–22.

Publisher's note

Bio-Byword Scientific Publishing remains neutral with regard to jurisdictional claims in published maps and institutional affiliations.