

A Comprehensive Analysis of a Case of Internal Carotid Artery Stenting

Meng Sun¹, Jun Wang², Yamei Wang^{1*}

¹Affiliated Hospital of Hebei University, Baoding 071000, Hebei Province, China

²College Hospital of Shijiazhuang University, Shijiazhuang 050000, Hebei Province, China

*Corresponding author: Yamei Wang, wym870428@sina.com

Copyright: © 2022 Author(s). This is an open-access article distributed under the terms of the Creative Commons Attribution License (CC BY 4.0), permitting distribution and reproduction in any medium, provided the original work is cited.

Abstract: With the development of science and technology and the continuous progress of interventional equipment, internal carotid artery stenting has become increasingly popular among patients in view of its advantages, which include high efficiency, minimally invasive, and fast postoperative recovery. It has grown importance as a surgical method for the treatment of severe internal carotid artery stenosis. This paper discusses a rare case of severe internal carotid artery stenosis and its management, where various types of pre-dilatation balloons were not able to be positioned in the stenting process. Relevant solutions have also been proposed in hope to provide a more theoretical and practical basis for clinical work.

Keywords: Severe internal carotid artery stenosis; Carotid artery stenting (CAS); Balloon pre-dilatation; Balloon positioning

Online publication: July 28, 2022

1. Case study

Liang XX, a 68-year-old male, was hospitalized on July 17, 2020, at 0905 hour due to dizziness. The patient developed dizziness two months before admission, accompanied by weak limbs, especially the left upper limb, which lasted for about 20 minutes and resolved spontaneously. He visited the outpatient department of the Affiliated Hospital of Hebei University in February 2020. Head and neck computed tomography angiography (CTA) showed severe stenosis at the right proximal internal carotid artery. In February 2020, he was diagnosed with hypertension, and his highest reading ever since being diagnosed was 150/95 mmHg. He has a smoking history of more than 40 years, in which he smokes 20 cigarettes a day.

His diagnoses were as follows: (1) severe stenosis at the right proximal internal carotid artery; (2) stage 2 hypertension (high risk).

His head and neck CTA showed severe stenosis at the right proximal internal carotid artery and severe calcification at the stenotic segment (**Figure 1**).

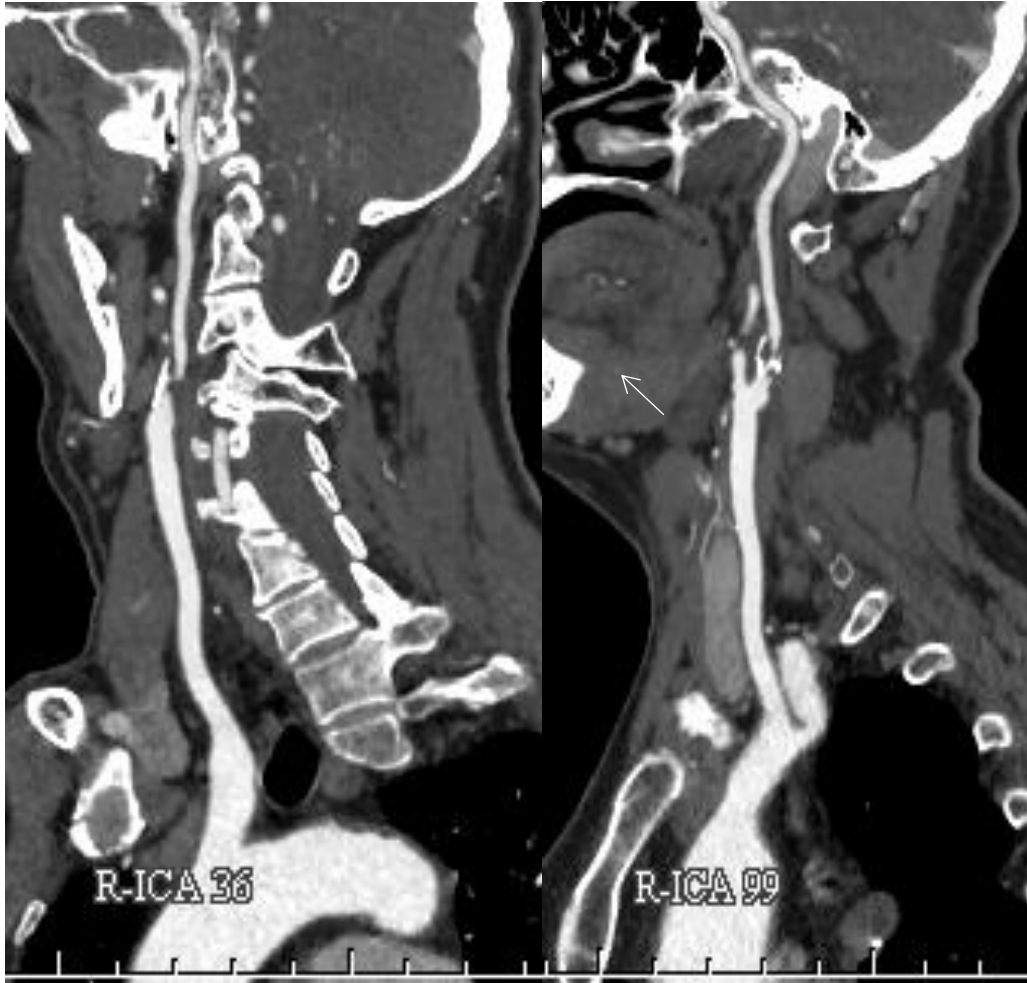


Figure 1. Right carotid CTA

An angiography of the aortic arch and the whole brain was performed on July 21, 2020 (**Figure 2**, **Figure 3**, **Figure 4**, and **Figure 5**).

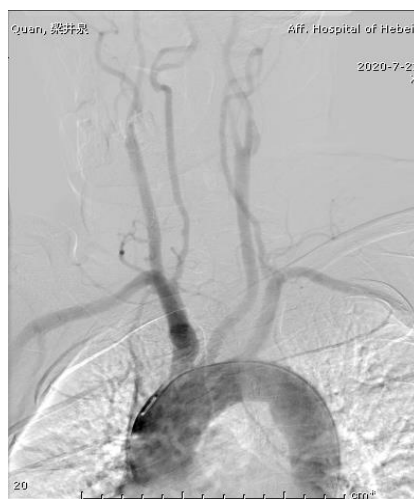

Figure 2. Aortic arch angiography

Type II aortic arch showed no obvious stenosis, but the occlusion of bilateral common carotid arteries and bilateral vertebral arteries were observed (**Figure 2**).

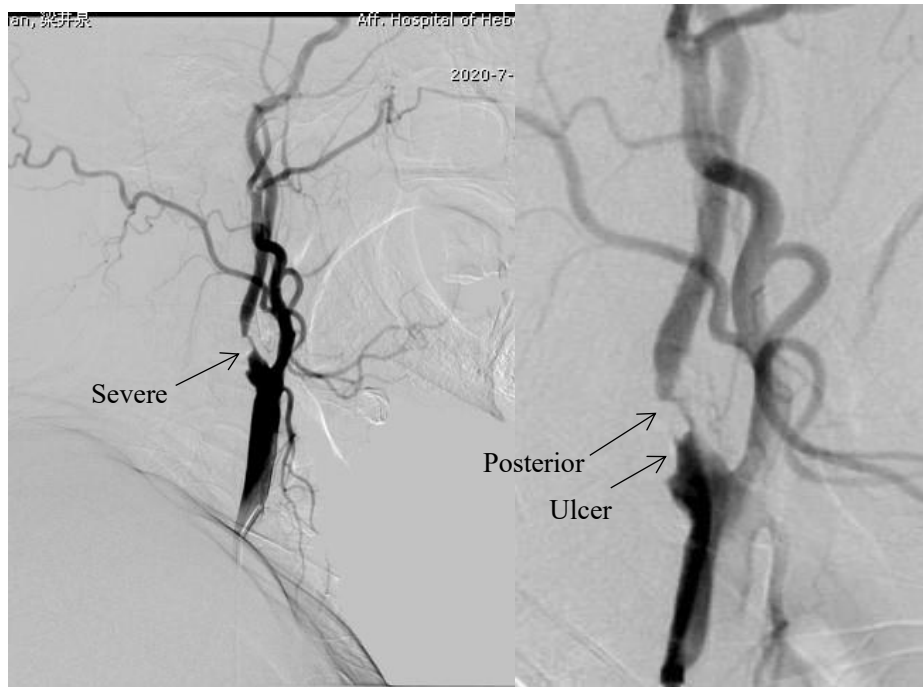


Figure 3. Right common carotid angiography

There was severe stenosis at the right proximal internal carotid artery, and the plaque was located on the posterior wall of the internal carotid artery. Small ulcers had formed on the posterior wall, and the stenosis was tortuous (**Figure 3**).

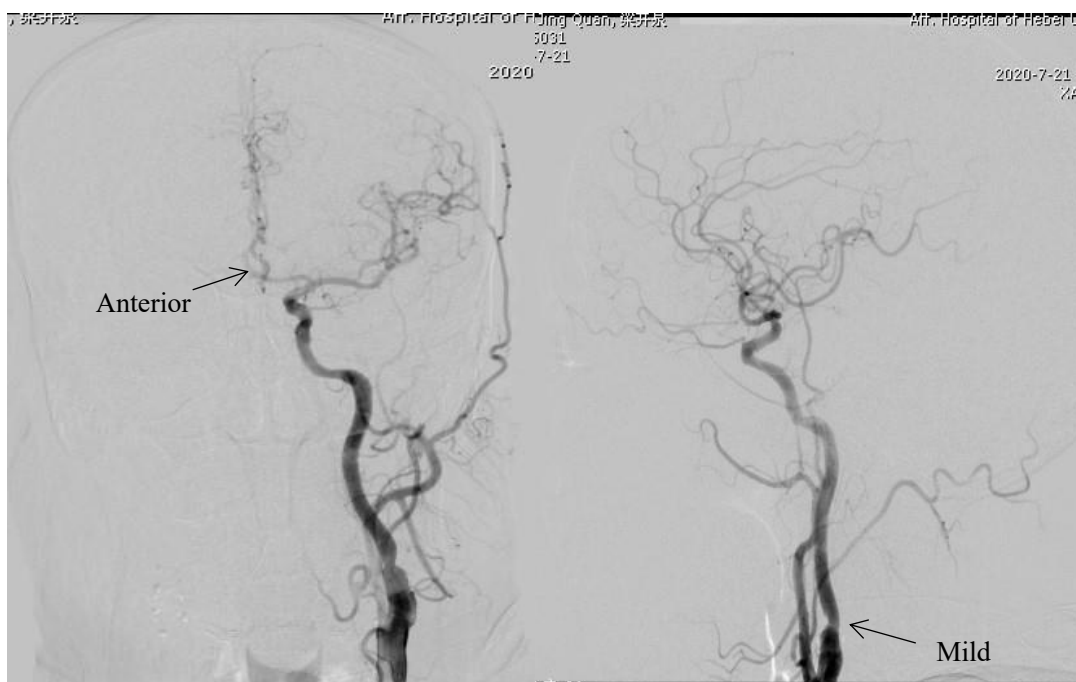

Figure 4. Left common carotid angiography

There was mild stenosis at the proximal part of the left internal carotid artery, the anterior communicating artery was patent, the bilateral anterior cerebral arteries were well-developed, and no severe stenosis was noted in the trunk or branches (**Figure 4**).

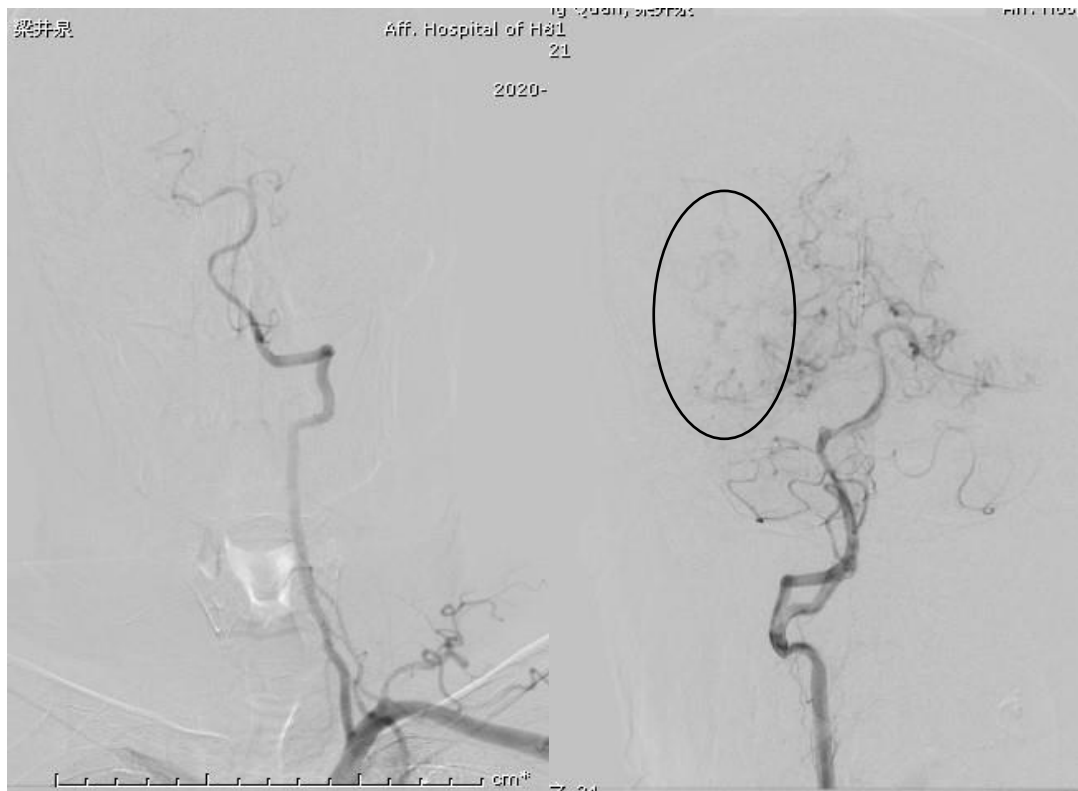


Figure 5. Left vertebral angiography

No severe stenosis was noted in the left vertebral artery and basilar artery as well as their branches. In the late phase of angiogram, the right posterior circulation could compensate for blood supply through the pia mater artery, like the right anterior circulation (**Figure 5**).

2. Interventional surgery

The surgical indication was severe stenosis ($> 70\%$) at the right proximal internal carotid artery with symptoms of cerebral ischemia. The surgical plan for the patient was stenting at the right proximal internal carotid artery. The anesthesia method was local infiltration anesthesia. Stenting of the right internal carotid artery was performed under local anesthesia on July 24, 2020.

The surgical process was as follows: under local infiltration anesthesia, the modified Seldinger technique was performed, in which the right common femoral artery was punctured, and an 8F femoral artery sheath was inserted; through the 8F femoral artery sheath, an 8F guide tube was inserted into the middle and upper segment of the right common carotid artery under the guidance of a loach guidewire and multifunctional catheter; under the guidance of path map, the 0.014-inch guidewire was inserted into the common carotid artery through the 8F guide tube to change the direction of the head end of the guidewire, reaching the distal end through the narrow segment of the internal carotid artery.

The guidewire was kept close to the anterior wall of the blood vessel, reaching the distal end through the narrow part, and avoiding stimulation to the plaque and the posterior wall ulcer as well as damage to the intima and formation of interlayer (**Figure 6**).

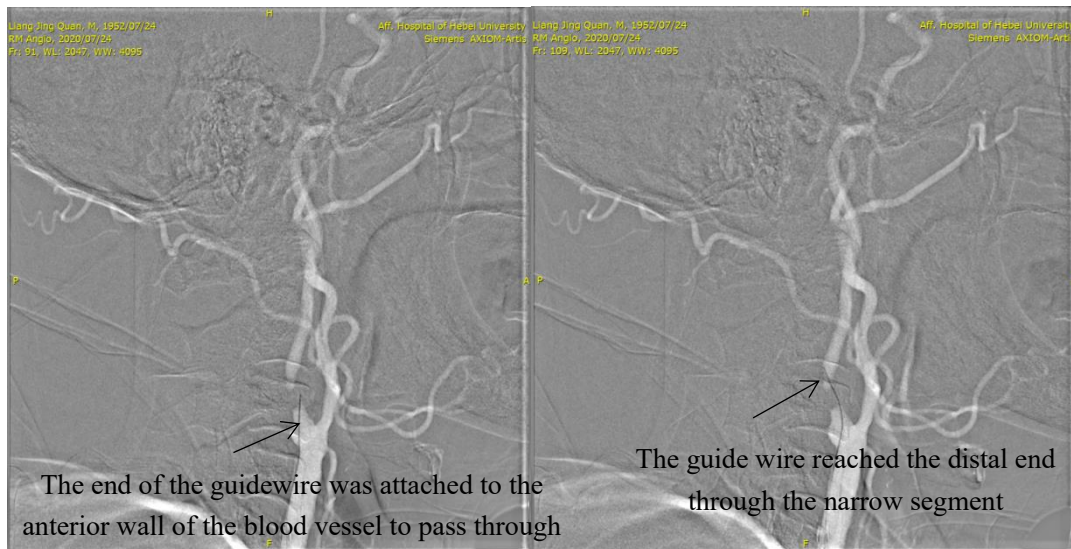


Figure 6. Path map of the right common carotid artery, with a micro-guidewire passing through the stenotic arterial segment

Under the guidance of the micro-guidewire, a carotid protective umbrella (Spider) (4 x 20 mm) was successfully placed. The 0.014-inch guidewire was withdrawn, and the pre-dilatation balloon (5 x 30 mm) was placed along the guidewire of the carotid umbrella, but the balloon could not pass through the narrow part. Although the balloon was replaced with a small-diameter balloon (2 x 15mm), the balloon still could not pass through the narrow part. By adjusting the position of the 8F guide catheter to provide more support to the balloon, the balloon still could not pass through the stenotic part. Even with a smaller diameter balloon (1.5 x 2 mm), it still could not pass through the stenotic part (**Figure 7**).

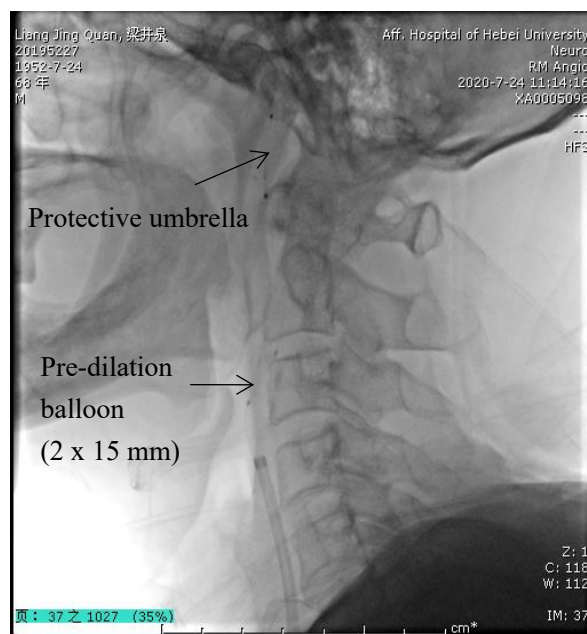


Figure 7. Position of guiding catheter, small balloon, and protective umbrella during the intervention

The following reasons were considered: severe stenosis and calcification at the lesion site, poor vascular compliance, and insufficient guidewire support. Therefore, the combination of the 0.014-inch guidewire and support catheter was inserted through the 8F guide tube, hoping that the support catheter could be inserted into the internal carotid artery to provide better support in place of the V-18 guidewire. However, the support catheter also could not pass through the stenotic part (**Figure 8**).

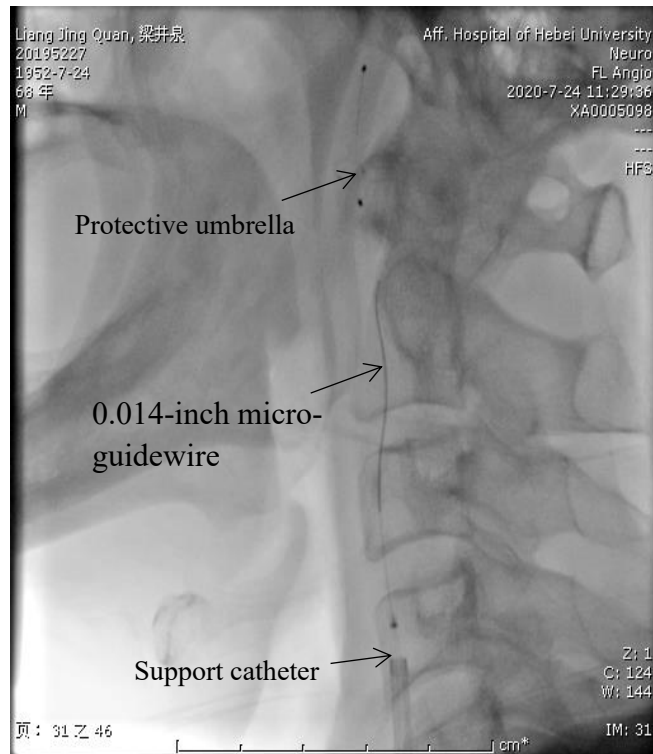


Figure 8. Micro-guidewire, support catheter, and umbrella locations

The balloon and supporting catheter could not pass through the lesion. The intervention was decided to be terminated after recovering the protective umbrella, but the recover catheter of the protective umbrella could not pass through the narrowed part. There was a dilemma during the surgery at that time; if the surgery continues, the pre-dilatation balloon cannot be positioned; if terminated, the protective umbrella cannot be recovered. The reason for the balloon's failure could be the severe stenosis and calcification at the lesion site, as well as the local spasm caused by repeated stimulation by the balloon. Therefore, the operation was suspended for 15 minutes in the hope that the spasm at the stenotic site would be relieved. After dilution with nitroglycerin 1 mg, the pre-dilatation balloon (1.5 x 2 mm) was inserted through the 8F guiding catheter, along the protective umbrella guidewire. After a large resistance, the balloon successfully reached the distal end of the stenotic segment and was then retracted to the stenotic segment; the stenotic segment was pre-dilatated twice (**Figure 9**).

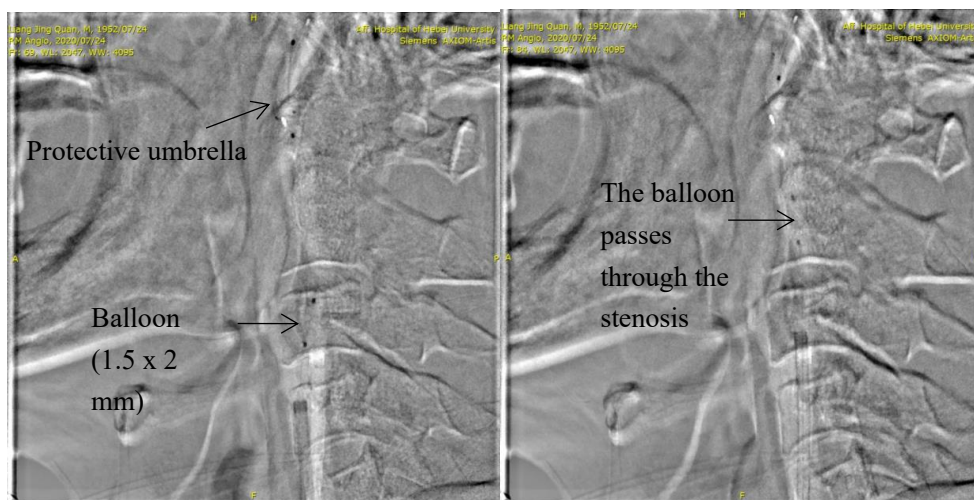


Figure 9. Small balloon passes through the stenosis

Although the small diameter balloon passed through the stenotic site, it still encountered great resistance at the site of the lesion (**Figure 9**).

After that, the 2 x 15 mm, 3 x 10 mm, and 4 x 30 mm balloons were pre-dilatated twice, respectively, while the 5 x 30 mm balloon was pre-dilatated once.

The small diameter balloon (2 x 15 mm) was positioned and pre-dilatated (**Figure 10**).

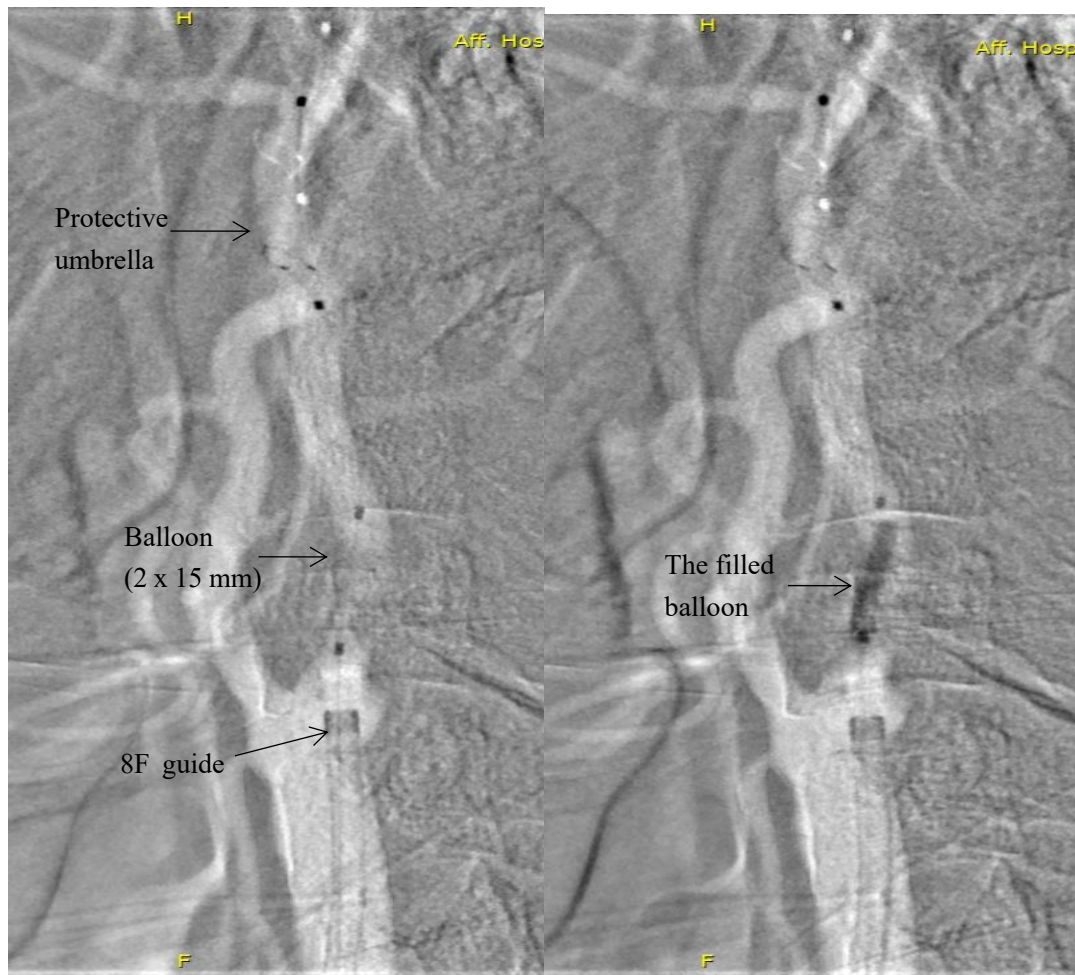


Figure 10. Application of small balloon to dilate stenotic arterial segment

A carotid artery stent (9-7 mm x 40 mm) was successfully implanted, the degree of stenosis improved significantly, and intracranial blood supply also improved (**Figure 11**).

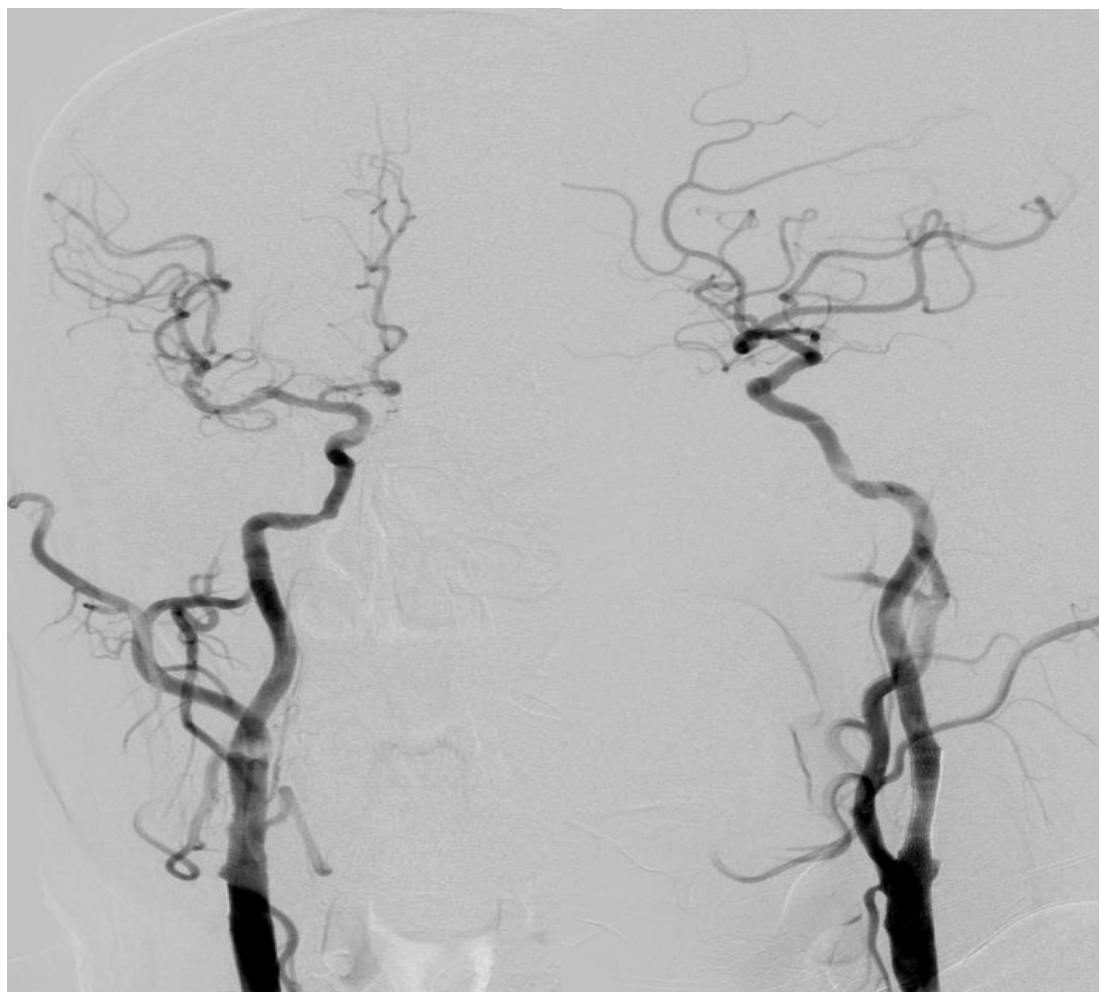


Figure 11. Postoperative right common carotid angiography

The protective umbrella was recovered, the 8F guiding catheter was withdrawn, and a surgical puncture point stapler was used for suture. The surgery was successful.

3. Discussion

Some patients with mild and moderate carotid stenosis may have no clinical symptoms. Patients with stenosis-associated clinical symptoms are categorized under “symptomatic carotid artery stenosis.” Symptomatic carotid bifurcation lesions have a high risk of recurrent ischemic stroke. According to the data of North American Symptomatic Carotid Endarterectomy Trial (NASCET) ^[1], for symptomatic patients treated with drugs, the degree of vascular stenosis was 70% to 99%; after two years of follow-up, the risk of ipsilateral stroke was 26%; on the contrary, the risk of ischemic stroke in patients with asymptomatic carotid bifurcation lesions was significantly lower. In the Asymptomatic Carotid Surgery Trial (ACST) ^[2], carotid ultrasound follow-up showed that patients with asymptomatic carotid stenosis with more than 60% stenosis and receiving drug treatment for more than five years had a stroke risk of 11%. Carotid endarterectomy (CEA) is currently the only method to remove atherosclerotic plaque and restore normal lumen and blood flow. By the 1980s, many centers in Europe and America began to conduct systematic research on CEA. A number of multicenter large sample randomized controlled studies showed that CEA is significantly better than drug treatment for severe carotid stenosis and symptomatic moderate carotid stenosis. The Carotid Revascularization Endarterectomy versus Stenting Trial (CREST) ^[3], published in 2010, is a randomized multicenter trial that compared the effects of CAS and CEA as well as

the incidence of complications in symptomatic and asymptomatic patients. During an average follow-up of 2.5 years in 2,502 patients, there was no significant difference in the incidence of major events between the two groups, which was 7.2% in the CAS group and 6.8% in the CEA group (HR 1.11, 95% CI 0.81-1.51). In 2016, the New England Journal of Medicine published the long-term follow-up results of CREST^[4]: 10 years after surgery, CEA (9.9%) was found better than CAS (11.8%) in terms of composite end point of death, stroke, and myocardial infarction, but there was no statistical significance to them; within five years after surgery, the proportion of ipsilateral stroke was very low (0.6% per year), which seemed to be slightly better than CAS (0.7%), but there was no significant difference between the two on the whole. Therefore, with the continuous progress of equipment and instruments, carotid stenting angioplasty (CAS) has been gradually popularized. With it being minimally invasive, having high efficiency and rapid postoperative recovery, along with its equivalent curative effect with CEA, CAS has increasingly favored by patients. CAS has become a method that can replace CEA, especially for those patients with high risk of CEA.

CAS has become a mature surgical method. Although the process is not complex, the risk is still very high. During CAS, difficulty in placing the balloon is common. Generally, it can be solved by changing to a small-diameter balloon. In this case study, balloons with various sizes cannot be successfully placed during the surgery. The reasons may be related to the following factors: (1) the lesion site is severely narrowed, calcified, and tortuous, with a significant decrease in vascular compliance; (2) the first pre-dilatation balloon (5 x 30 mm) was too large, and it stimulated the narrowed part, causing spasm; in that case, when smaller balloons are attempted, they failed to pass through the stenotic part; if the 2 x 15 mm pre-dilatation balloon was selected first, the surgery may have been relatively smooth; (3) the lesion segment is tortuous, and the supporting force of the umbrella guidewire is not enough to change the shape of the narrowed segment; hence, the balloon cannot pass through. For these reasons, the pre-dilatation balloon cannot be in place, and the internal carotid artery protective umbrella cannot be recovered, thus placing the surgery in a difficult situation. The solutions to this include the following: (1) in preoperative evaluation, it is necessary to make an effective evaluation of the lesion site, especially in imaging; (2) adequate surgical plans should be made; (3) it should be expected that the balloon will not be easily placed, therefore a 0.014-inch guidewire should be used to carry a small diameter balloon for pre-dilatation of the lesion site, while direct pre-dilatation via a large diameter balloon should not be used as far as possible; (4) in view of carotid spasm, vasodilator or vasospasm prophylaxis drugs may be given.

In conclusion, CAS has become a mature surgical method for the treatment of carotid stenosis. This case is a rare situation, where the balloon cannot be positioned. Relevant solutions have been proposed, hoping to provide a more theoretical and practical basis for clinical work.

Disclosure statement

The authors declare no conflict of interest.

References

- [1] Barnett HJM, Taylor DW, Eliasziw M, et al., 1998, Benefit of Carotid Endarterectomy in Patients with Symptomatic Moderate or Severe Stenosis. *New England Journal of Medicine*, 339(20): 1415–1425.
- [2] Mayberg MR, Wilson SE, Yatsu F, et al., 1991, Carotid Endarterectomy and Prevention of Cerebral Ischemia in Symptomatic Carotid Stenosis. *JAMA*, 266(23): 3289–3294.
- [3] Brott TG, Hobson RW, Howard G, et al., 2010, Stenting Versus Endarterectomy for Treatment of Carotid-Artery Stenosis. *New England Journal of Medicine*, 363(1): 11–23.

- [4] Brott TG, Howard G, Roubin GS, et al., 2016, Long-Term Results of Stenting Versus Endarterectomy for Carotid-Artery Stenosis. *New England Journal of Medicine*, 374(11): 1021–1031.

Publisher's note

Bio-Byword Scientific Publishing remains neutral with regard to jurisdictional claims in published maps and institutional affiliations.