

A Case Report on Pulmonary Benign Metastasizing Leiomyoma with Recurrent Uterine Fibroids

Zheng Gong¹, Zegang Liu^{2*}

¹Department of Thoracic Surgery, The Affiliated Hospital of Yunnan University, Kunming 650021, Yunnan Province, China

²Department of General Surgery, 920 Hospital of the Joint Service Support Force of the Chinese People's Liberation Army, Kunming 650021, Yunnan Province, China

*Corresponding author: Zegang Liu, gongzhengv5@sina.com

Copyright: © 2022 Author(s). This is an open-access article distributed under the terms of the Creative Commons Attribution License (CC BY 4.0), permitting distribution and reproduction in any medium, provided the original work is cited.

Abstract: Pulmonary benign metastasizing leiomyoma (PBML) is a type of benign metastasizing leiomyoma (BML), which metastasizes to lungs. In view of the rarity and nonspecific imaging characteristics of PBML, this condition is easily misdiagnosed as malignant lung cancer. This is a case report of a 39-year-old lady in whom multiple bilateral lung nodules were found during a health checkup and was diagnosed with PBML. The patient had recurrent uterine fibroids and underwent myomectomy twice, 7 years and 3 years ago, respectively, before the diagnosis of PBML was made. This patient was asymptomatic, and regular examinations were normal. Her laboratory investigations were all within normal range. Computed tomography (CT) showed multiple nodules in bilateral lungs. In order to confirm the disease, thoracoscopic nodule resection and tissue biopsy were performed. Hematoxylin eosin (HE) staining showed spindle-shaped cells, while immunohistochemical staining revealed positive for desmin, smooth muscle actin (SMA), estrogen receptor (ER), and progesterone receptor (PR), which are all PBML markers. The patient was followed-up without any further treatment. After 8 months of follow-up, CT scan revealed an increased number of nodules. This is unique case because of the recurrence of uterine fibroids, which means that the patient is susceptible to it. Our report may give a new insight to the relationship between the susceptibility of uterine fibroids and the onset and progression of PBML.

Keywords: Pulmonary benign metastasizing leiomyoma (PBML); Benign metastasizing leiomyoma (BML); Myomectomy; Uterine fibroid

Online publication: September 28, 2022

1. Introduction

Benign metastasizing leiomyoma (BML) is a rare disease that mainly occurs in premenopausal women who have had history of myomectomy ^[1]. The most common metastatic site of BML is the lung, which is also referred to as pulmonary benign metastasizing leiomyoma (PBML) ^[2]. The onset time of PBML ranges from 3 months to 20 years after myomectomy, with an average time of 14.9 years ^[3]. Since it lacks specific characteristics, PBML is diagnosed by taking several factors into account, including the medical history, clinical manifestations, imaging features, and pathological examination ^[4]. There are many hypotheses proposed in attempt to explain the origins and pathogenesis of PBML; however, there is no one satisfactory theory that can explain the etiology and pathogenesis of PBML.

A unique case of PBML, whereby the patient had recurrent uterine fibroids and underwent myomectomy twice, is discussed in this paper in an attempt to give a new insight to the relationship among uterine fibroids, PBML, and hormones.

2. Case presentation

A 39-year-old Chinese lady was admitted to The Affiliated Hospital of Yunnan University in November 2020 due to an increasing number of lung nodules, which had been detected a year ago. She had no obvious symptoms, such as cough, hemoptysis, chest pain, and dyspnea. In July 2019, multiple nodules were found in both her lungs (**Figure 1A**) during a health checkup in a local hospital, and further follow-up was recommended instead of specific treatment. After a year later, CT scan showed that the nodules increased in number (**Figure 1B**). Hence, she was admitted to our hospital for further diagnosis and treatment.

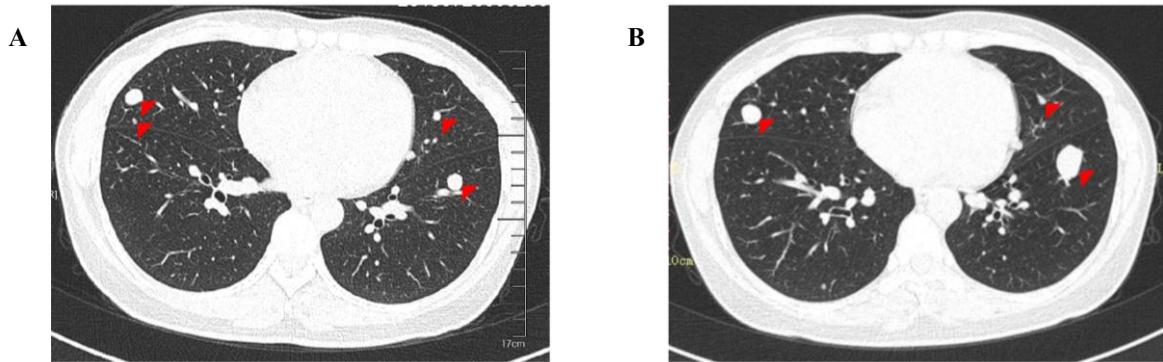


Figure 1. Chest CT images; (A) A CT scan image showing multiple lung nodules in July 2019; (B) A CT scan image showing that the nodules had enlarged and increased in number in November 2020

In 2013, she was diagnosed with uterine fibroids in a local hospital and underwent myomectomy. After surgery, she delayed going to the hospital for timely clinical check. In May 2017, she was diagnosed with recurrence of uterine fibroids and underwent the second myomectomy in a local hospital. Half a year after the second myomectomy, ultrasound examination was done with no uterine fibroids found (**Figure 2A**). However, in March 2020, her uterine fibroids recurred once again, and she was diagnosed with recurrent uterine fibroids via ultrasound imaging (**Figure 2B**).

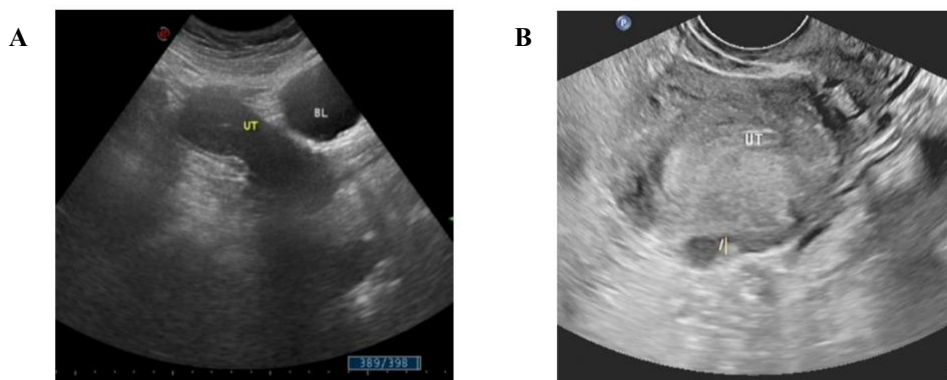


Figure 2. Ultrasound images of the uterus; (A) No uterine fibroids were found during ultrasound examination in November 2017; (B) Fibroids were found in the posterior wall of the uterus in March 2020

She denied a history of diabetes, hypertension, coronary artery disease, and infections. She had no history of smoking or family history of lung disease. Her complete blood count, hemoglobin, tumor markers (CEA, CA125, CA15-3, etc.), electrocardiogram (ECG), and echocardiography were normal. A CT scan of the chest was done for the patient in our hospital. The images suggested the presence of multiple nodules in bilateral lungs, in which the largest was located in the inferior lobe of the left lung with a size of 1.0*1.5 mm (**Figure 3**). The initial diagnosis made was multiple lung metastases.

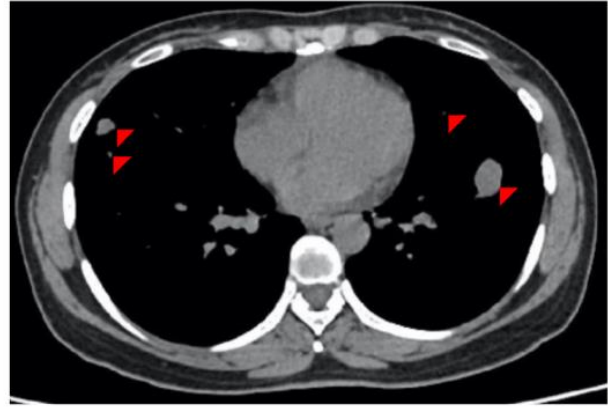
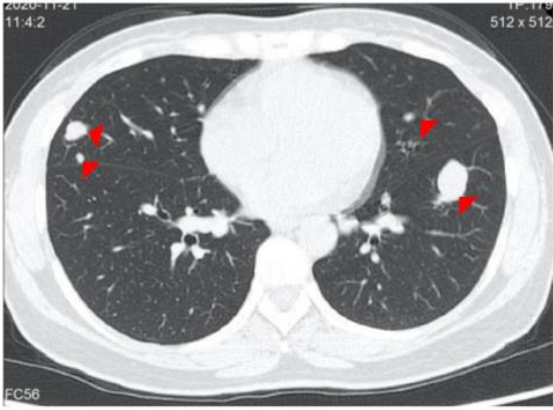


Figure 3. Chest CT images after admission

In order to further confirm the diagnoses, thoracoscopic nodule resection of the middle lobe of the right lung and subsequent tissue biopsy were performed. Hematoxylin eosin (HE) staining showed spindle-shaped cells without nuclear atypia (**Figure 4**), while immunohistochemical staining was positive for desmin (+), smooth muscle antibody (SMA) (+), estrogen receptor (ER) (+), and progesterone receptor (PR) (+) (**Figure 5**).

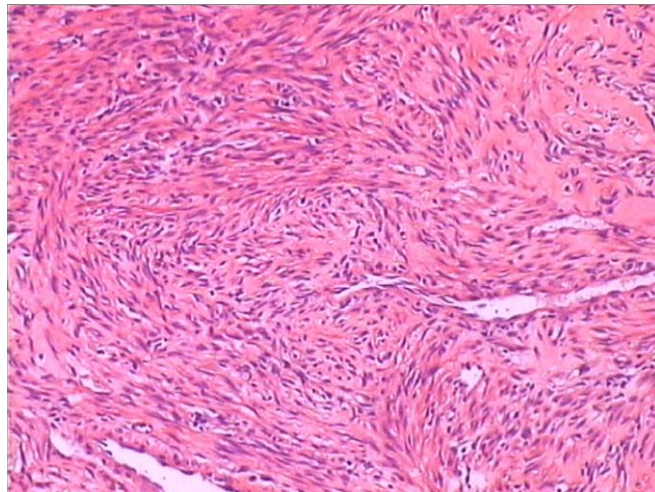


Figure 4. HE staining of nodule tissues taken from the middle lobe of the right lung (×400)

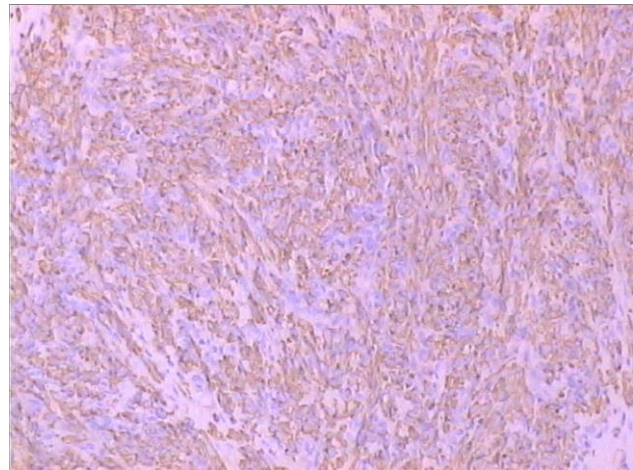
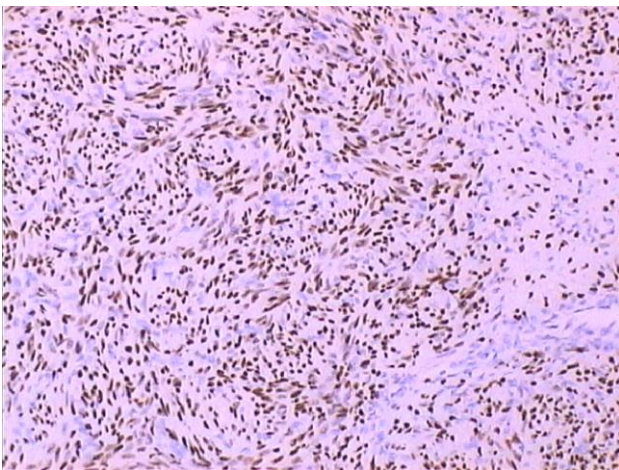


Figure 5. Immunohistochemical staining of nodule tissues taken from the middle lobe of the right lung (×400)

With comprehensive consideration of the patient's medical history, clinical manifestations, and examination results, this patient was diagnosed with PBML. Since there were no obvious symptoms, and there were only multiple tiny nodules, the patient was followed-up. In July 2021, 8 months after being diagnosed with PBML, CT scan was done for the patient, revealing that the nodules increased in number compared with 8 months ago (**Figure 6**).

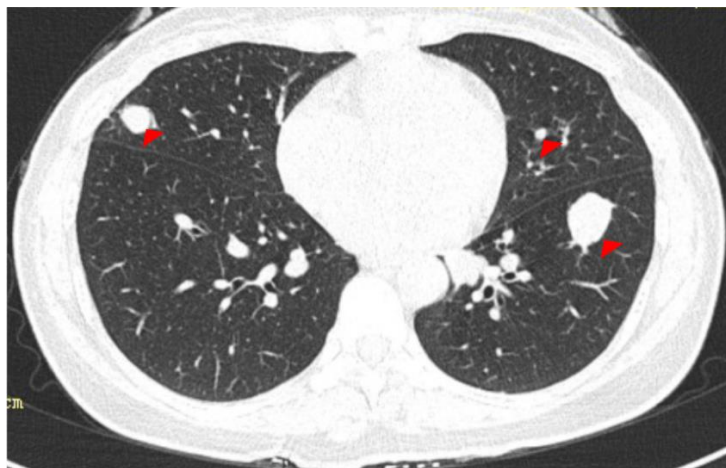


Figure 6. A CT scan image of the chest during follow-up 8 months after diagnosis

3. Discussion

PBML is a rare disease and most of the facts about this disease are derived from case reports. In 1939, Steiner PE first reported a patient who was found with multiple nodules in the lungs during postmortem examination; this was the first report about PBML^[5]. Now, after about a century, we know that PBML, a type of BML, is a disease with benign histological manifestations, usually occurring in premenopausal women. By analyzing patients' medical history, most patients with PBML have a history of uterine fibroid treatment. PBML often has no specific symptoms or radiological findings. Hence, it is easily misdiagnosed as metastasis if only its imaging features are taken into account. This is because its imaging features are similar to those of metastatic tumors. Histology is the key to make a definite diagnosis of PBML. By analyzing tissue sections, well-differentiated smooth muscle cells could be seen in HE staining and relative biomarkers could be tested positive in immunohistochemistry staining^[6]. In order to make an accurate diagnosis, medical history, especially gynecological surgery experience, radiological examination, and histological examination, need to be considered.

PBML patients often have a history of myomectomy^[3,7]. Uterine fibroids are benign tumors that are common and occur in over 70% of women^[8,9]. It usually occurs in women of bearing age and may shrink in postmenopausal women. ER and PR, the receptors of estrogen and progesterone, which have been considered as the key factors of uterine fibroids, are expressed in uterine fibroid tissues^[10,11]. Interestingly, the age of onset and existence of ER/PR in uterine fibroids are similar to PBML^[12,13]. Hormone therapy is a major treatment for uterine fibroids besides surgery; in some reports, it is also effective for PBML^[14,15]. All these evidences link the occurrence and development of PBML with uterine fibroids. A well accepted hypothesis to explain the etiology of PBML is the transfer of smooth muscle cells from the uterus to distant sites, including the lungs, through blood vessels or the lymphatic system^[16]. However, this hypothesis does not provide explanation for PBML patients who do not co-present with uterine fibroids^[17]. Understanding the clinical manifestations and pathologies between these two diseases, we have reason to believe that there exists a more common pathogenesis. The majority of PBML patients who were previously reported had undergone myomectomy only once. Here, we report a patient who underwent myomectomy for uterine fibroids twice before the diagnosis of PBML was made, in which the onset time is shorter than average.

Moreover, after 8 months, during her follow-up, the size of the lung nodules had increased. This clinical phenomenon suggests the patient's susceptibility to uterine fibroids and the progression of PBML. With comprehensive analysis of the close relationship between uterine fibroids and PBML, the patient's susceptibility to uterine fibroids, and the shorter onset time, we believe that there is a correlation between the onset frequency of uterine fibroids and the onset time and progression of PBML. Additionally, we think that hormones may play an important role in this process. However, since the pathogenesis of PBML is complex, more research needs to be done to confirm our hypothesis.

In summary, this is a case report of a patient with PBML, who had recurrent uterine fibroids and underwent myomectomy twice. The etiology of PBML is not clear up to now. Based on our case, we propose that the onset time and progression of PBML may be related to an individual's susceptibility to uterine fibroids, and hormones may play an important role in this process.

Disclosure statement

The authors declare no conflict of interest.

References

- [1] Goto T, Maeshima A, Akanabe K, et al., 2012, Benign Metastasizing Leiomyoma of the Lung. *Ann Thorac Cardiovasc Surg*, 18(2): 121–124.
- [2] Zhang J, Dong A, Cui Y, et al., 2019, Diffuse Cavitory Benign Metastasizing Leiomyoma of the Lung, *Thorax*, 74(2): 208–209.
- [3] Kayser K, Zink S, Schneider T, et al., 2000, Benign Metastasizing Leiomyoma of the Uterus: Documentation of Clinical, Immunohistochemical and Lectin-Histochemical Data of Ten Cases. *Virchows Arch*, 437(3): 284–292.
- [4] Pacheco-Rodriguez G, Taveira-DaSilva AM, Moss J, 2016, Benign Metastasizing Leiomyoma. *Clin Chest Med*, 37(3): 589–595.
- [5] Steiner PE, 1939, Metastasizing Fibroleiomyoma of the Uterus: Report of a Case and Review of the Literature. *Am J Pathol*, 15(1): 89–110.
- [6] Jiang H, Ma L, Qi XW, et al., 2021, Pulmonary Benign Metastasizing Leiomyoma: A Case Report and Literature Review. *Ann Palliat Med*, 10(5): 5831–5838.
- [7] Fan R, Feng F, Yang H, et al., 2020, Pulmonary Benign Metastasizing Leiomyomas: A Case Series of 23 Patients at a Single Facility. *BMC Pulm Med*, 20(1): 292.
- [8] Baird DD, Dunson DB, Hill MC, et al., 2003, High Cumulative Incidence of Uterine Leiomyoma in Black and White Women: Ultrasound Evidence. *Am J Obstet Gynecol*, 188(1): 100–107.
- [9] Cramer SF, Patel A, 1990, The Frequency of Uterine Leiomyomas. *Am J Clin Pathol*, 94(4): 435–438.
- [10] Benassayag C, Leroy MJ, Rigourd V, et al., 1999, B. Estrogen Receptors (ERalpha/ERbeta) in Normal and Pathological Growth of the Human Myometrium: Pregnancy and Leiomyoma. *Am J Physiol*, 276(6): E1112–E1118.
- [11] Stewart EA, Laughlin-Tommaso SK, Catherino WH, et al., 2016, Uterine Fibroids. *Nat Rev Dis Primers*, 2: 16043.
- [12] Aoki K, Yamamoto T, Terauchi R, et al., 2021, Benign Metastasizing Leiomyoma in Femur and Thigh with a History of Uterine Leiomyoma: A Case Report and Literature Review. *J Obstet Gynaecol Res*, 47(2): 812–817.

- [13] Lee SR, Choi YI, Lee SJ, et al., 2017, Multiple Cavitating Pulmonary Nodules: Rare Manifestation of Benign Metastatic Leiomyoma. *J Thorac Dis*, 9(1): E1–E5.
- [14] Perez-Lopez FR, 2015, Ulipristal Acetate in the Management of Symptomatic Uterine Fibroids: Facts and Pending Issues. *Climacteric*, 18(2): 177–181.
- [15] Rivera JA, Christopoulos S, Small D, et al., 2004, Hormonal Manipulation of Benign Metastasizing Leiomyomas: Report of Two Cases and Review of the Literature. *J Clin Endocrinol Metab*, 89(7): 3183–3188.
- [16] Nucci MR, Drapkin R, Dal Cin P, et al., 2007, Distinctive Cytogenetic Profile in Benign Metastasizing Leiomyoma: Pathogenetic Implications. *Am J Surg Pathol*, 31(5): 737–743.
- [17] Barnas E, Ksiazek M, Ras R, et al., 2017, Benign Metastasizing Leiomyoma: A Review of Current Literature in Respect to the Time and Type of Previous Gynecological Surgery. *PLoS One*, 12(4): e0175875.

Publisher's note

Bio-Byword Scientific Publishing remains neutral with regard to jurisdictional claims in published maps and institutional affiliations.