

Adenomatoid Odontogenic Tumor in Mandible

Roberto de A Azevedo¹, Braulio C Junior², Lucio CS Andrade¹, Carlos HS de Castro^{2*}

¹Hospital Santo Antônio, Santo Antônio de Jesus 44571-013, Bahia, Brazil

²Federal University of Bahia, Ondina 40170-110, Salvador, Brazil

*Corresponding author: Carlos H. S. de Castro, carloshsilveirac@hotmail.com

Copyright: © 2023 Author(s). This is an open-access article distributed under the terms of the Creative Commons Attribution License (CC BY 4.0), permitting distribution and reproduction in any medium, provided the original work is cited.

Abstract: The adenomatoid odontogenic tumor is a relatively infrequent lesion that mainly affects females in the second decade of life, and its predicted site is the anterior region of the mandible with the lesion usually associated with the crown of the tooth. In this study, a case of adenomatoid odontogenic tumor in the anterior region of the mandible is reported together with its clinical, radiological, and histological findings and surgical treatment.

Keywords: Adenomatoid odontogenic tumor; Adenoameloblastoma; Odontogenic tumor

Online publication: April 19, 2023

1. Introduction

Adenomatoid odontogenic tumor (AOT) is a relatively uncommon lesion of odontogenic epithelium origin, which was first described by Gash in 1934, however, it was Stafne (1948), who is the first to recognize it as an entity. Until then, the lesion was considered as a variant of ameloblastoma, and was called as odonAOTmeloblastoma^[1]. Only in 1969, Philipsen and Birn established its current denomination, followed by recognition by the World Health Organization (WHO), and in 1971 it was recognized as a benign neoplasm of ectodermal origin^[2,3].

Clinically, its presented as a slow-growing lesion, with little or no painful symptoms, and causing bone expansion. It affects the region of canines and premolars, both in the maxilla and mandible with a ratio of 2:1 respectively^[4-6].

In addition, it is considered as an infrequent lesion that represents approximately 3% of total the total odontogenic tumors cases. Philipsen (1991) conducted a study with 499 cases of AOT, in which he found that the female gender is more affected compared to male gender with a proportion of 2:1 respectively, and it is diagnosed at a restricted age range between 10 to 30 years with most cases appearing at the second decade of life^[7-10]. The intra-osseous is more common in the maxilla than in the mandible with a ratio of 2.1:1 respectively, and the peripheral is found almost exclusively in the anterior region of the maxilla^[11,12].

Radiographically, AOT presents itself as a radiolucent area with well-defined contours by a cortical bone, and depending on the stage of maturation of the lesion, it may or may not contain radiopaque foci compatible with calcified zones^[13-15]. In contrast, the lesion may or may not be associated with an unerupted tooth, of which 60% are canines^[16,17].

In addition, Philipsen subclassified the AOT according to two variants^[8] as described below:

(1) Follicular: Where the tumor is associated with the crown of an unerupted tooth, and corresponds to

73 % of the intra-bone lesions. This variant is often confused with dentigerous cyst.

- (2) Extra-follicular: Where the tumor is not associated with an unerupted tooth, but is found in an interradicular position, and in the most cases causing root separation of the units which are neighboring the lesion. In these cases, the differential diagnosis is made with residual cyst and lateral periodontal cyst.

Histologically, the proliferation of epithelial cells is similar to the preameloblasts that is group in masses, forming a duct-like structures called pseudoducts. In these masses, the cells are in a cuboidal shape [18,19]. In some areas, these pseudoducts are filled with eosinophilic material, and in other regions this material is found between these pseudo-ducts [10,20-22].

The diagnosis of AOT should be well differentiated from other lesions, such as ameloblastoma. Since the prognosis of AOT is much more doubtful, due to its aggressiveness and its association with unerupted teeth, therefore the dentigerous cyst should be included [9,23,24]. With the presence of residual cyst, lateral periodontal cyst, and based on the presence of radiopaque foci, a differential diagnosis should be made by calcifying the lesions into an odontogenic cyst or epithelial odontogenic tumor [4]. Considering that AOT is a benign and nonaggressive tumor, characterized by a slow and progressive growth, low tendency to recurrence, and by the presence of a capsule indicating the absence of invasion of the surrounding tissues, the treatment choice is conservative surgery by excision and curettage [17,19,25]. Further, depending on the position and involvement of the unerupted tooth associated with the lesion, a decision will be made either the tooth should be preserved or not with orthodontic traction [6].

This article reports a case of Adenomatoid Odontogenic Tumor located in the mandibular symphysis region, further addressing its clinical, radiographic, and histological characteristics, with the conservative surgical treatment of choice.

2. Case report

Patient (MNCS), 17 years old, female, Faioderma, from Jequie-BA, attended the Oral and Maxillofacial Surgery Service at the Santo Antonio Hospital: Social Works Irma Dulce Association with a complaint of swelling in the tooth mental region. During anamnesis she reported that the swelling had been present for about 6 months, without pain or bleeding, and it caused a great esthetic deficit (**Figure 1**). The extraoral examination revealed a significant volume increase in the mandible anterior region, while the intraoral examination showed a swelling in the region between the premolars with poor dental positioning of the units involved with an absence of the unit 3.2. On palpation, the lesion had a firm consistency, and the mucosa had normal-looking coloration or feature (**Figure 2**).

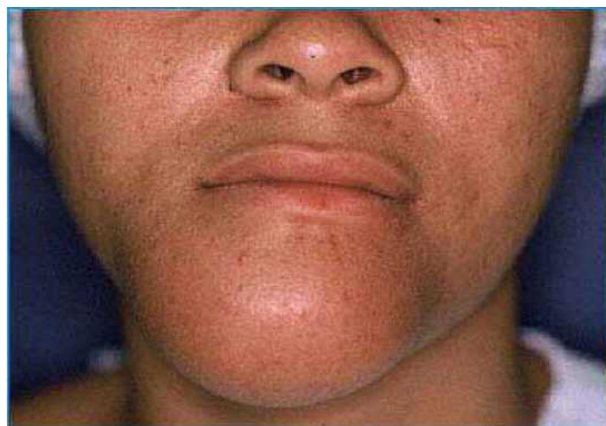

Figure 1. Presenting an increase in volume in the mental region

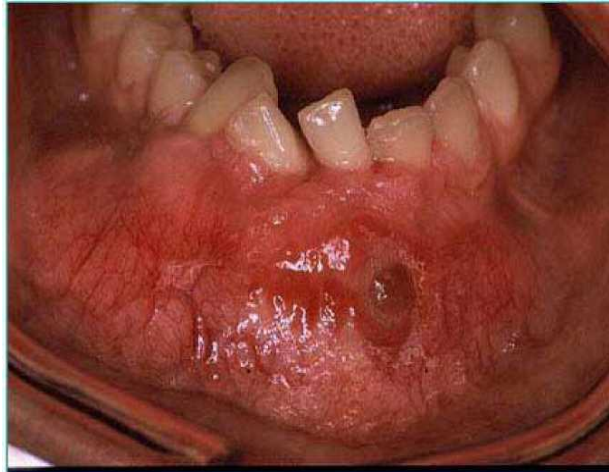

Figure 2. Presents an increase in volume with intra-oral observation

Panoramic and occlusal radiographic exams were performed on the patient, which showed a well delimited radiolucent zone with few radiopaque foci inside, completely involving the dental unit 3.2. It extended from the 1st left pre-molar to the 2nd right pre-molar, and the roots of the units involved were quite divergent and some had resorption processes (**Figure 3**). An incisional biopsy was performed under local anesthesia, together with an aspiration puncture which confirmed the solid nature of the lesion. The histological findings of a cyst wall lined by the proliferation of epithelial cells with central formation of acinar-similar cells with central eosinophilic material and deposition of calcium spherocytes confirmed the diagnosis of AOT, which contradicted the initial clinical suspicion of ameloblastoma, due to the clinical and radiographic features of the lesion.

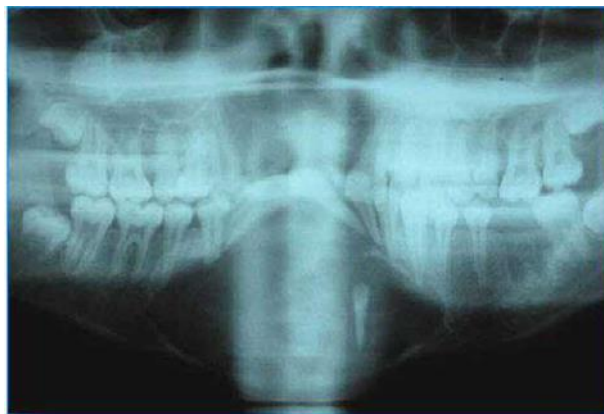


Figure 3. It presents a radiographic view of the Iesao showing the unit 3.2 included

The tumor was removed by curettage, under general anesthesia, followed by verification of the normality as requested by the preoperative. The tumor was encapsulated, which made its complete excision and preservation of the mentonian neurovascular bundles bilaterally. The dental unit 3.2 was removed together with the lesion, and the other units were kept for further endodontic treatment. During the 3-month period, the patient was followed up and there was no report of postoperative discomfort, paresthesia or any sign of the lesion recurrence. The panoramic radiograph of about 100 days after surgery further confirms this clinical finding, and showed a bone neo-formation in the region. The patient continues to follow up, and placed under endodontic treatment for the dental units near the lesion (**Figure 4** and **Figure 5**).

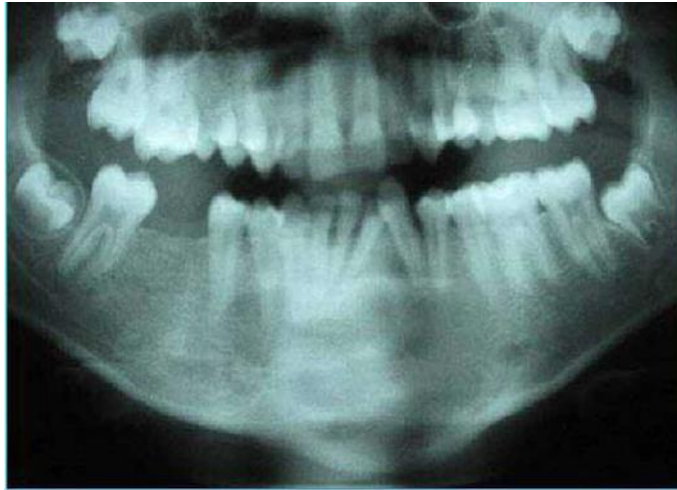

Figure 4. Radiographic aspect showing bone formation observed after 100 days

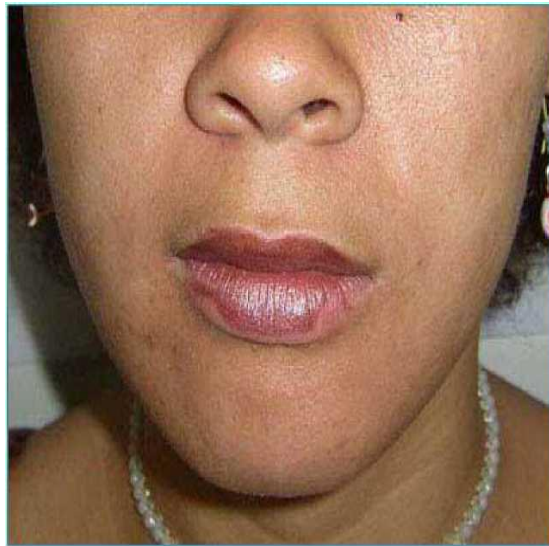

Figure 5. Facial appearance of the patient at the 100-day return visit demonstrating harmonious facial contour

3. Discussion

The AOT has well defined characteristics, with the highest incidence found in the maxilla. In most of the AOT cases it is associated with retained teeth, and mostly related to canine teeth. The size generally varies between 1.5 to 3 cm, however, there are reports of tumors size of approximately 9 cm^[3]. According to the reports, it is generally located in the anterior region of the maxilla, but in this case the lesion was observed in the anterior region of the mandible. It measures in its greatest diameter 0.5 cm, and is associated with an incisor tooth.

There is a predominance of this type of tumor in females, with a 2:1 ratio in female to male, and a greater frequency of incidence is in the second decade of life^[2,4,16,20-23]. These mentioned characteristics were found in the present case, in which the patient was female, and 17 years old.

The AOT incidence is more common in the maxilla than in the mandible with a ratio occurrence is 2.1:1 respectively, which differs from the case that is found in our service, as the AOT was presented in the mandible anterior region^[2,6]. In most of the cases the radiographic image showed a radiolucent, well defined, circumscribed, unilocular area associated with an unerupted upper canine^[8,26], which further differs from the case that is reported here, where it was associated with a lower lateral incisor.

It should be noted that there is no misdiagnosis between AOT and ameloblastoma, because although

both lesions have odontogenic origin, they differ in age, sex, incidence rate, anatomical location, type of treatment and recurrence, and also have distinctive histological aspects ^[1,4]. In the present study, the presence of large increase in volume, leads to the clinical suspicion of ameloblastoma, however, the incisional biopsy prior to the final treatment revealed the true nature of the tumor, allowing the elaboration of an adequate treatment plan.

AOT is treated surgically by enucleation and curettage, with exclusive removal of the lesion, and with no tendency towards recurrence ^[4,15,17-19]. In the present case, the surgical approach allowed new formation of the bone in this region, verified by control radiography, as well as the return of the roots that had been found displaced from their initial position.

It is important to report that radiographically it becomes practically impossible in making a precise diagnosis, because it can be confused with a series of other pathologies conditions. The conservative surgical intervention is emphasized as the treatment of choice in cases of adenomatoid odontogenic tumors and the pathological structure, including the affected tooth should be mandatorily sent to histopathological evaluation.

Disclosure statement

The authors declare no conflict of interest.

References

- [1] Philipsen HP, Birn H, 1969, The Adenomatoid Odontogenic Tumor; Ameloblastic Adenomatoid Tumor; Or Adenoameloblastoma. *Acta Pathol Microbiol Scand*, 1969(75): 375.
- [2] Philipsen HP, Reichart PA, Zhang KH, 1991, Adenomatoid Odontogenic Tumor: Biologic Profile Based on 499 Cases. *J Oral Pathol Med*, 1991(20): 149.
- [3] Lee JK, Lee KB, Hwang BN, 2000, Adenomatoid Odontogenic Tumor: A Case Report. *J Oral Maxillofac Surg*, 2000(58): 1161–1164.
- [4] Reis SRA, et al., 1991, Tumor Odontogenico Adenomatoido: Relato e um caso (Adenomatoid Odontogenic Tumour: Case Report). *Rev. Fac. de Odontologia/UFBA*, 1991(10): 11.
- [5] Philipsen HP, Reichart PA, Nikai H, 1997, The adenomatoid Odontogenic Tumour (AOT): An Update. *Oral Med Pathol*, 1997(2): 55–60.
- [6] Philipsen HP, Reichart PA, 1998, Adenomatoidodontogenic Tumor: Facts and Figures. *Oral Oncology*, 1998(35): 123–125.
- [7] Cudney N, Persico J, Cordell KG, et al., 2008, Adenomatoid Odontogenic Tumor Developing in Association with an Odontoma: Report of a Case. *Quintessence Int*, 39(8): 693–697.
- [8] Nonaka CFW, Souza LB, Quindere LB, 2007, Tumor Odontogenico Adenomatoido Associado a Cisto Dentiger: Relato de um Caso Incomum (Adenomatoid Odontogenic Tumour Associated with Dentigerous Cyst: Unusual Case Report). *Rev Bras Otorrinolaringol*, 73(1): 135–137.
- [9] Ide F, Mishima K, Saito I, et al., 2008, Rare Peripheral Odontogenic Tumors: Report of 5 Cases and Comprehensive Review of the Literature. *Oral Surg Oral Med Oral Pathol Oral Radiol Endod*, 106(4): 22–28.
- [10] Nigam S, Gupta SK, Chaturvedi KU, 2005, Adenomatoid Odontogenic Tumor: A Rare Cause of Jaw Swelling. *Braz Dent J*, 16(3): 251–253.
- [11] Santos JN, Lima FO, Romerio P, et al., 2008, Adenomatoid Odontogenic Tumor: An Unusual Case Exhibiting Cribriform Aspect. *Quintessence Int*, 2008(39): 777–781.

- [12] Friedrich RE, Scheuer HA, Zustin J, 2009, Adenomatoid Odontogenic Tumor (AOT) of Maxillary Sinus: Case Report with Respect to Immunohistochemical Findings. *In vivo*, 23(1): 111–116.
- [13] Garg D, Palaskar S, Shetty VP, et al., 2009, Adenomatoid Odontogenic Tumor: Hamartoma or True Neoplasm: A Case Report. *J Oral Sci*, 51(1): 155–159.
- [14] Chuan-Xiang Z, Yan G, 2007, Adenomatoid Odontogenic Tumor: A report of a Rare Case with Recurrence. *J Oral Pathol Med*, 36(7): 440–443.
- [15] Toledo OA, et al., 1994, Tumor Odontogenico Adenomatoides. *RGO*, 42(1): 31-34.
- [16] Ogata DC, Ioshii SO, Sassi LM, et al., 2008, Tumor Odontogenico Adenomatoides Extrafolicular: Uma Apresentaçao Infrequente de um Tumor Raro (Extrafollicular Adenomatoid Odontogenic Tumor: An Unusual Presentation of a Rare Tumor). *Rev Bras Cir cabeça PesCoCo*, 37(4): 234–235.
- [17] Vasconcelos BCE, Silva EDO, Frota R, et al., 2003, Tumor Odontogenico Adenomatoides em Maxila (Adenomatoid Odontogenic Tumour in Maxilla). *Rev Cir Traumat Buco-Maxilo-Fac*, 3(3): 15-19.
- [18] Vasconcelos BCE, Frota R, Cardoso AB, et al., 2008, Tumor Odontogenico Adenomatoides (Adenomatoid Odontogenic Tumor). *Rev Bras Otorrinolaringol*, 74(2): 315–318.
- [19] Ajagbe HA, Daramola JO, Junaid TA, 1985, Adenomatoid Odontogenic Tumor in a Black African Population: Report of Thirteen Cases. *J Oral and Maxillofac Surg*, 43(9): 683-687.
- [20] McGuff HS, Alderson GL, Jones AC, et al., 2008, Oral and Maxillofacial Pathology Case of the Month. Adenomatoid odontogenic tumor, *Tex Dent J*, 125(12): 1192–1195.
- [21] Silva MS, Freire EG, Anjos ED, et al., 2004, Tumor Odontogenico Adenomatoides: Relato de Caso CrniCo (Adenomatoid Odontogenic Tumor: A Case report). *Rev Cir Traumatol Buco-maxilo-fac*, 4(4): 246–251.
- [22] Swadison S, Dhanuthai K, Jai Kittivong A, et al., 2008, Adenomatoid Odontogenic Tumors: An Analysis of 67 Cases in a Thai Population. *Oral Surg Oral Med Oral Pathol Oral Radiol Endod*, 105(2): 210–215.
- [23] Botelho TL, Araujo MBG, Bueno TS, et al., 2005, Tumor Odontogenico Adenomatoides: Relato de Caso CrniCo (Adenomatoid Odontogenic Tumor: Report of Case). *Rev Bras Patol Oral*, 4(3): 177–181.
- [24] Borges SP, Santos LAN, Paula AMB, et al., 2005, Tumor Odontogenico Adenomatoides (Adenomatoid Odontogenic Tumor). *Rev Bras Odontol*, 62(1/2): 113–114.
- [25] Stafne EC, 1948, Epithelial Tumors Associated with Developmental Cysts of the Maxilla: Report of 3 cases. *Oral Surg*, 1948(1): 887.

Publisher's note

Bio-Byword Scientific Publishing remains neutral with regard to jurisdictional claims in published maps and institutional affiliations.