

Study on the Impact of Post-Mastectomy Radiotherapy on Immediate Breast Reconstruction and Complications: A Meta-Analysis

Wen Li[†], Manman Sun, Lihao Zheng, Yibo Jiang, Nan Ba*

Department of Radiation Oncology, Fifth Affiliated Hospital of Zhengzhou University, Zhengzhou City, Henan Province 450000, China

[†]First author: Wen Li, 1973954087@qq.com

*Corresponding author: Nan Ba, bananbanana@163.com

Copyright: © 2024 Author(s). This is an open-access article distributed under the terms of the Creative Commons Attribution License (CC BY 4.0), permitting distribution and reproduction in any medium, provided the original work is cited.

Abstract: *Background and objective:* Immediate breast reconstruction not only reduces the number of surgeries for patients after mastectomy but also decreases psychological and physical trauma, making it increasingly popular. However, there is currently no consensus on the integration of post-mastectomy radiotherapy (PMRT) with reconstruction techniques. This review evaluates the impact of PMRT on complications following immediate breast reconstruction, providing guidance for clinical treatment decisions. *Methods:* PubMed, Web of Science, Embase, and other databases were searched for studies published in the past 15 years on outcomes of implant-based breast reconstruction in the context of radiotherapy to identify articles for analysis. RevMan 5.4 software was used to analyze the risks of seroma, infection, wound dehiscence, flap necrosis, implant exposure, capsule contracture, and reconstruction failure. *Results:* A total of 11 relevant studies were included, comprising 6323 cases of immediate breast reconstruction. It was found that breasts receiving postoperative irradiation had a significantly increased risk of complications, with statistically significant differences in seroma ($P = 0.004$), infection ($P < 0.00001$), wound dehiscence ($P = 0.04$), implant exposure ($P < 0.00001$), capsule contracture ($P < 0.00001$), and reconstruction failure ($P < 0.00001$). There was no statistically significant difference in flap necrosis ($P = 0.88$). *Conclusion:* The results indicate that postoperative radiotherapy significantly increases the risk of complications for patients undergoing immediate implant-based reconstruction. Preventive measures may be taken in advance with the assistance of healthcare providers if necessary.

Keywords: Breast cancer; Immediate breast reconstruction; Radiotherapy; Post-mastectomy; Complications

Online publication: July 22, 2024

1. Introduction

For women worldwide, breast cancer has become the highest incidence of cancer. In 2022 alone, the number of new cases of female breast cancer in the world exceeded 2.3 million (23.85%), far more than lung cancer (9.4%) and colorectal cancer (8.9%). At the same time, approximately 665,000 people die from breast cancer, making it the leading cause of death among women worldwide^[1]. Some studies have speculated that the burden of breast

cancer will continue to rise due to population growth and aging ^[2]. More than 3 million new cases and 1 million deaths are expected to occur each year after 2040. Although the incidence of breast cancer has never decreased, due to the application of various anti-tumor therapies, the survival rate and period of patients have been significantly improved. Therefore, the current concern is improving the quality of life of the patients. Mastectomy is a common treatment option for patients with early-stage breast cancer ^[3]. In addition, prophylactic mastectomy may be a good option for patients with inherited breast cancer who are at risk for *BRCA1* or *BRCA2* gene mutations ^[4]. However, it is worth noting that mastectomy may have an impact on the patient's appearance and psychology, so techniques such as breast reconstruction and breast endoscopy are increasingly popular.

In women with locally advanced breast cancer, post-mastectomy radiotherapy (PMRT) has been shown to reduce local recurrence and improve survival in patients with node-positive disease ^[5]. Despite its therapeutic advantages, PMRT increases the risk of complications and generally has poor cosmetic results for women undergoing breast reconstruction. Current NCCN guidelines recommend auto-reconstruction or tissue dilator implantation in patients receiving PMRT ^[6]. A study based on trends in breast reconstruction over the past decade confirmed that more women are currently undergoing implant reconstruction than autologous tissue reconstruction ^[7]. While these reconstruction options have their limitations, immediate breast reconstruction based on dilators or prostheses is gaining in popularity as it reduces the psychological trauma of losing a breast while avoiding a second surgery. The effect of PMRT on immediate breast reconstruction has been extensively studied, however, there is a lack of relevant reviews or meta-analyses. In this study, 11 pieces of literature on relevant topics were retrospectively analyzed, and the effects of PMRT on postoperative complications after immediate breast reconstruction were described. This study provides insight into reconstruction surgery and the risks and complications of postoperative adjuvant radiotherapy so that patients can make a better choice in terms of treatment options.

2. Data and methods

2.1. Search method

We conducted a systematic electronic search on PubMed, Web of Science, Embase, Cochrane Library, CNKI, Wanfang Database, and Vip.com from December 2023 to February 2024. The Chinese keywords were “post-operative breast cancer,” “prosthesis implantation,” and “radiotherapy.” The keywords searched were “breast cancer,” “prosthesis implantation” and “radiation therapies.” The Boolean operator and or is used between keywords and medical subject words “breast cancer” (MeSH), “radiation therapy” (MeSH), “immediate” (MeSH), and “pseudoweight reconstruction” (MeSH).

2.2. Determination of inclusion and exclusion criteria

The inclusion or exclusion of a study was determined by reviewing the title and abstract by two researchers, followed by a thorough reading of the entire article for additional screening based on the following criteria: (1) literature on radiation therapy for breast reconstruction in the last 15 years; (2) all patients had breast cancer; all patients underwent skin-sparing mastectomy, regardless of whether the nipple-areola complex was preserved; (3) the reconstruction method was either immediate one-stage fake weight reconstruction or immediate two-stage expander reconstruction; (4) and there was sufficient raw data in the study to calculate the number of cases in each group and the number of cases with complications. Studies were excluded if they were conference guidelines, animal experiments, literature reviews, meta-analyses, lacked a comparison between the postoperative radiotherapy group and the non-radiotherapy group, or had repeated publication, incomplete data, or too many patients lost to follow-up.

2.3. Data extraction

The main complications of concern in this study were seroma, infection, incision rupture, flap necrosis, implant exposure, capsular contracture, and reconstruction failure. Infections include those requiring oral antibiotics, those requiring intravenous antibiotics, and those requiring surgical procedures. Flap necrosis can range from partial necrosis that is cured with conservative treatment to complete necrosis that requires additional surgery. Capsular contracture was introduced into the Spear-Baker classification^[8], which included category III breast reconstruction with moderate hardness and category IV severe capsular contracture with unacceptable aesthetic results and/or requiring surgical intervention. Reconstruction failure is defined as the loss of a tissue expander or implant, without regard to replacement outcomes. Data extracted from the 11 selected papers included the first author, year of publication, study design, duration of follow-up, patient information (number of breast reconstruction cases, age, body mass index), specific reconstruction method (phase 1 with direct implantation or phase 2 with tissue expander), radiotherapy protocol including technique, dose, and frequency, and whether acellular dermal matrix (ADM) was used, expander state. The NOS scale^[9] was used to evaluate the literature, with a full score of 9.

2.4. Data processing and analysis

We evaluated the effect of radiation therapy on the outcome of immediate breast prosthesis/expander reconstruction and compared the combined risk of 7 complications, including seroma, infection, incision rupture, flap necrosis, implant exposure, capsular contracture, and reconstruction failure, in patients who received and did not receive radiation after immediate reconstruction. The relative risk (RR) with the corresponding 95% confidence interval (CI) was calculated using the Mantel-Haenszel test in RevMan 5.4. In each analysis, the Cochran Q test and the I^2 test were used to assess inter-study heterogeneity. $50 < I_2 < 75\%$ is moderately heterogeneous, and if $P > 0.1$ and I^2 value $\leq 50\%$, the study is considered homogeneous and a fixed-effect model is used. Otherwise, a random effects model is used. The possibility of publication bias was assessed by generating funnel plots.

3. Result

3.1. Literature search results

A total of 627 references were found in the first screening. After screening by two researchers, a total of 11 studies met the criteria and were included for subsequent analysis (**Figure 1**). All studies were cohort studies, of which 4 were retrospective studies^[10-13] (level III evidence) and the rest were prospective studies (level II evidence). A total of 6323 cases of immediate breast reconstruction were analyzed (**Table 1**), of which 1583 received postoperative radiotherapy and 4740 did not. Six studies^[12,14-18] used tissue dilators for two-stage pseudo-weight reconstruction, four studies^[10,11,13,19] used two methods for immediate reconstruction, including one-stage direct implantation and two-stage dilator reconstruction, and one study^[20] added results for auto implantation. All cases in the two studies^[13,15] used the acellular dermal matrix (ADM), and three studies^[17,19,20] used ADM selectively. Six of the 11 studies^[12-16,20] described detailed information on PMRT. Although there was some heterogeneity in chest wall enhancement or high dose use, the PMRT regimen was generally consistent across all studies, including the dose per segmentation, the frequency of segmentation, and the total dose administered. Two studies^[17,20] all used 3D conformal radiotherapy (3D-CRT), two studies^[10,11] used 3D-CRT and intensity-modulated radiotherapy (IMRT), and the remaining studies did not specify the radiotherapy technique. When patients received radiotherapy, 5 studies had fully dilated dilators^[13-16,18], while 2 studies had partially dilated dilators^[10,12] (**Table 2**).

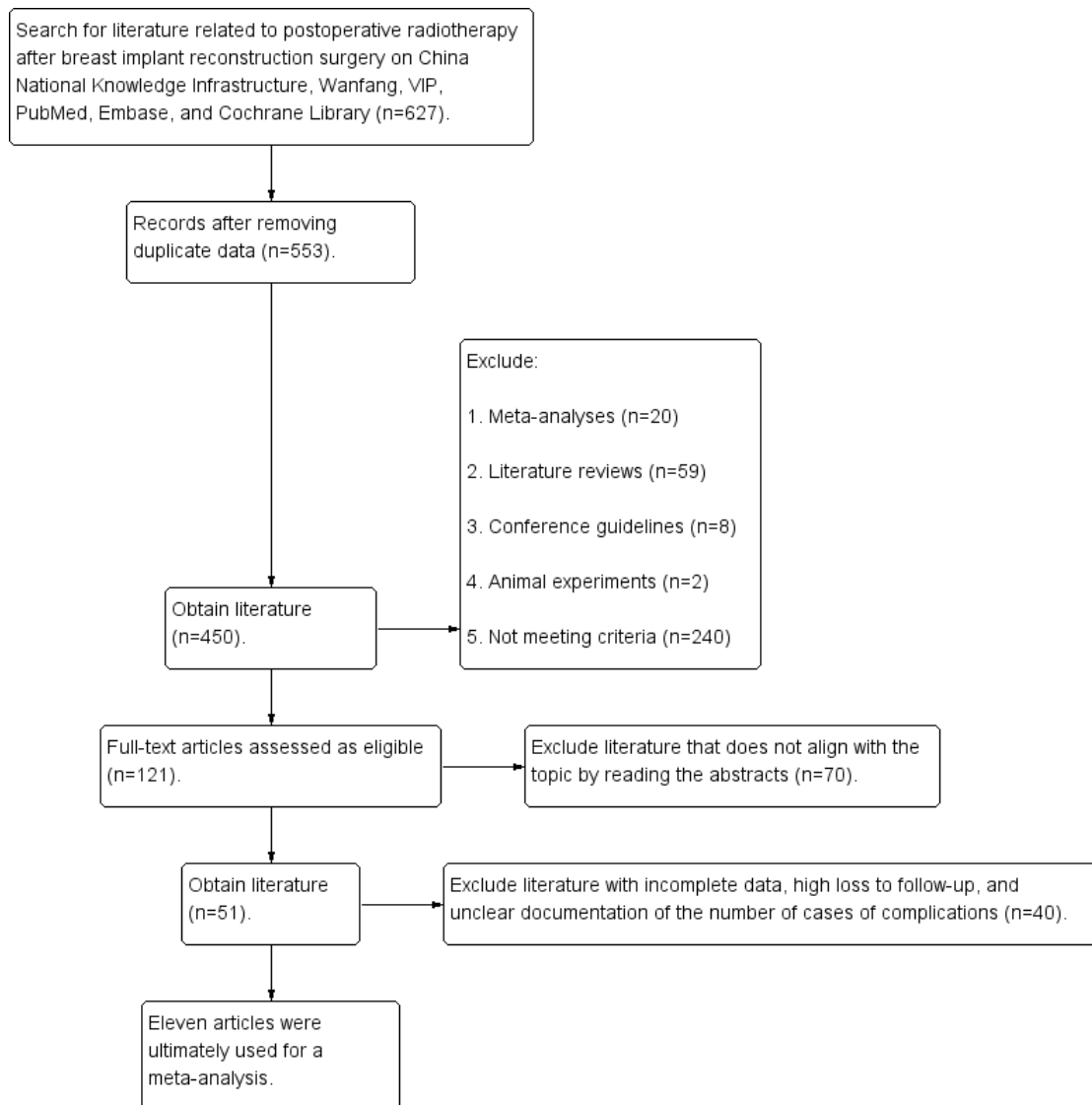


Figure 1. Flow chart of the literature search

Table 1. Characteristics of included studies

First author and year of publication	Country	Study type (cohort study)	Median follow-up time (month)	Radiotherapy group			Non-radiotherapy group			A way to rebuild immediately	NOS score
				Total number of breast reconstruction	Age (years)	BMI	Total number of breast reconstruction	Age (years)	BMI		
George (2022) ^[15]	America	Prospective	84.3	309	-	-	352	-	-	Two stages	8
Langshuang (2022) ^[12]	China	Retrospective	47.7	221	36.7 ^b	21.5 ^b	59	40.5 ^b	21.5 ^b	One stage/ two stages	7
Katherine (2020) ^[18]	America	Retrospective	-	36	49.6 ^b	32.7 ^b	165	51.4 ^b	30 ^b	Two stages	7
George (2019) ^[13]	America	Prospective	6.2	231	46.5 ^a	-	580	49.1 ^a	-	One stage/ two stages/ autologous reconstruction	8
Alessia (2017) ^[20]	Britain	Retrospective	33.3	38	46.7 ^b	26.1 ^b	84	48.7 ^b	24.9 ^b	One stage/ two stages	7
Horatiu (2016) ^[17]	America	Retrospective	24.1	125	-	26.1 ^a	533	-	24.8 ^a	One stage/ two stages	7

Table 1 (Continued)

First author and year of publication	Country	Study type (cohort study)	Median follow-up time (month)	Radiotherapy group			Non-radiotherapy group			A way to rebuild immediately	NOS score
				Total number of breast reconstruction	Age (years)	BMI	Total number of breast reconstruction	Age (years)	BMI		
Peter (2015) ^[13]	America	Prospective	30.1	304	46.1 ^b	26.3 ^b	1,486	47.8 ^b	24.6 ^b	Two stages	8
Adelyn (2014) ^[16]	America	Prospective	37.3	113	46.1 ^b	23.2 ^b	339	47.3 ^b	23.2 ^b	Two stages	6
Hani (2014) ^[19]	America	Prospective	25	113	43.9 ^b	23.9 ^b	727	46.9 ^b	23.8 ^b	One stage/ two stages	8
Scott (2012) ^[11]	America	Prospective	15.2	56	44.9 ^a	25.8 ^a	355	46.2 ^a	24.3 ^a	Two stages	7
Monica (2011) ^[14]	Mexico	Prospective	40.2	37	41.0 ^a	-	60	40.0 ^a	-	Two stages	7

Note: a, median; b, mean value; BMI, body mass index

Table 2. Radiotherapy regimens

First author and year of publication	The use of LD flap	Use of ADM	Radiotherapy plan				
			Radiotherapy technique	Total number	Total dose (GY)	Chest wall enhancement	Expander state
George (2022) ^[15]	No	Selective use	3D-CRT	25–28	50–50.4	Selectivity	-
Langshuang (2022) ^[12]	No	No	3D-CRT/IMRT	25–28	50–50.4	Selectivity	Demi-inflation
Katherine (2020) ^[18]	All use	No	EBRT	-	-	-	Demi-inflation
George (2019) ^[13]	Selective use	Selective use	3D-CRT	-	45–68	Selectivity	-
Alessia (2017) ^[20]	-	All use	EBRT	15	40	-	Complete expansion
Horatiu (2016) ^[17]	-	-	3D-CRT/IMRT	-	-	Selectivity	-
Peter (2015) ^[13]	No	No	EBRT	-	-	Entirety	Complete expansion
Adelyn (2014) ^[16]	No	No	EBRT	25-28	50	-	Complete expansion
Hani (2014) ^[19]	No	Selective use	EBRT	-	-	-	-
Scott (2012) ^[11]	No	All use	EBRT	-	-	-	Complete expansion
Monica (2011) ^[14]	No	-	EBRT	25	50	-	Complete expansion

Abbreviations: LD flap, latissimus dorsi flap; ADM, acellular dermal matrix; 3D-CRT, three-dimensional conformal radiation therapy; IMRT, intensity modulated radiation therapy; EBRT, external beam radiotherapy

3.2. Effect of radiation therapy on complications after immediate breast reconstruction

3.2.1. Serum tumor

Eight studies were included for heterogeneity test, and the results showed that $I^2 = 0\%$ ($< 50\%$), $P = 0.58$ (> 0.1), the heterogeneity was small, and the fixed-effect model was used for analysis. The results of the meta-analysis

showed that radiotherapy increased the risk of seroma after immediate breast reconstruction, with a significantly increased risk of 1.77 times in patients who received radiotherapy after reconstruction compared with those who did not receive radiotherapy (95% CI: 1.20–2.61), and the difference was statistically significant ($P = 0.004$). Further details are shown in **Figure 2**.

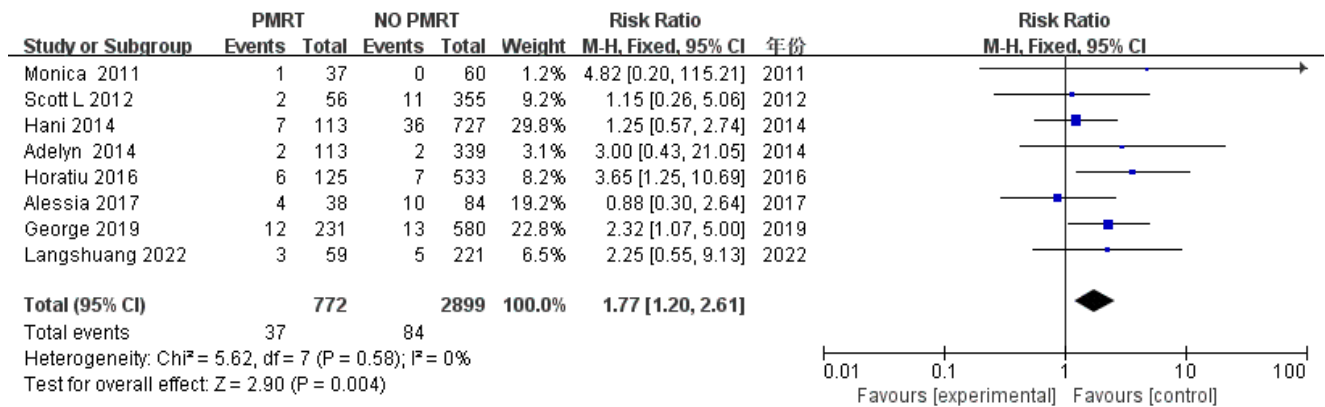


Figure 2. Forest plot for the impact of PMRT on seroma

3.2.2. Infection

Nine studies were included for heterogeneity test, and the results showed that $I^2 = 18\%$ ($< 50\%$), $P = 0.29$ (> 0.1), the heterogeneity was small, and the fixed-effect model was used for analysis. The results of the meta-analysis showed that radiotherapy increased the risk of infection after immediate breast reconstruction, and the risk of seroma was significantly increased by 2.07 times (95% CI: 1.77–2.42) in patients who received radiotherapy after reconstruction compared with those who did not receive radiotherapy, and the difference was statistically significant ($P < 0.00001$). Further details are shown in **Figure 3**.

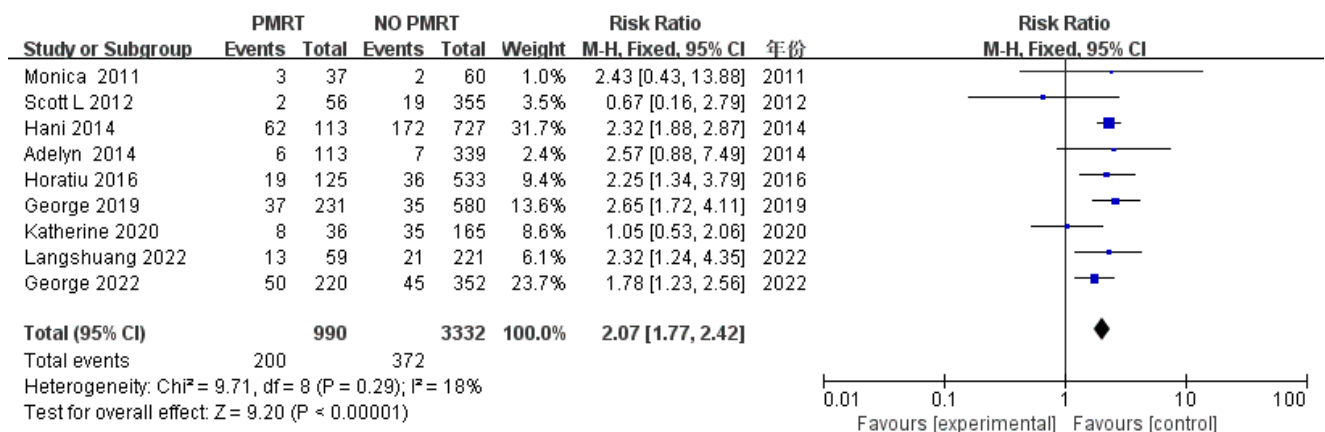


Figure 3. Forest plot for the impact of PMRT on infection

3.2.3. Disruption of wound

Four studies were included for heterogeneity test, and the results showed that $I^2 = 33\%$ ($< 50\%$), and Q -test $P = 0.21$ (> 0.1), the heterogeneity was small, and the fixed-effect model was used to combine the effect size. Meta-analysis results showed that radiotherapy increased the risk of incision dehiscence after immediate reconstruction, and the risk of incision dehiscence was significantly increased by 1.8 times in patients receiving radiotherapy compared with those who did not receive radiotherapy (RR: 1.80; 95% CI: 1.02–3.17), and the difference was statistically significant ($P = 0.04$). Further details are shown in **Figure 4**.

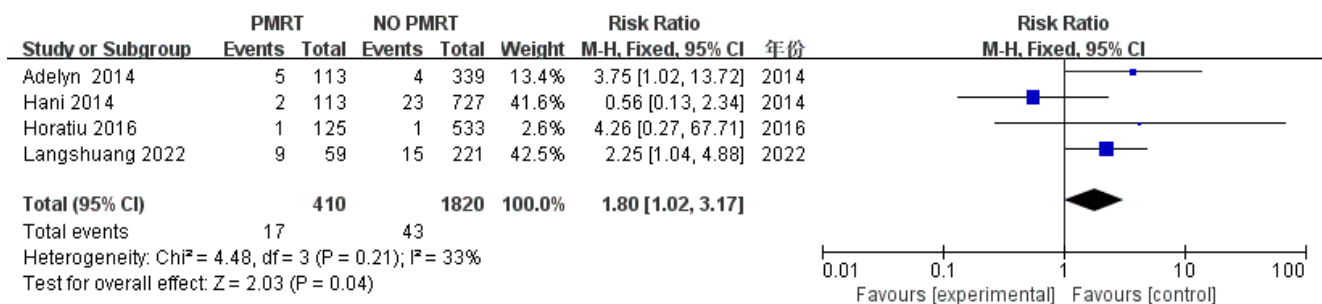


Figure 4. Forest plot for the impact of PMRT on wound dehiscence

3.2.4. Flap necrosis

Four studies were included for heterogeneity test, and the results showed that $I^2 = 0\%$ ($< 50\%$), and Q-test $P = 0.72$ (> 0.1), the heterogeneity was small, and the fixed-effect model was used to combine the effect size. Meta-analysis results showed that radiotherapy increased the risk of flap necrosis after immediate reconstruction (RR: 1.05; 95% CI: 0.88–1.90), however, the difference was not statistically significant ($P = 0.88$). Further details are shown in Figure 5.

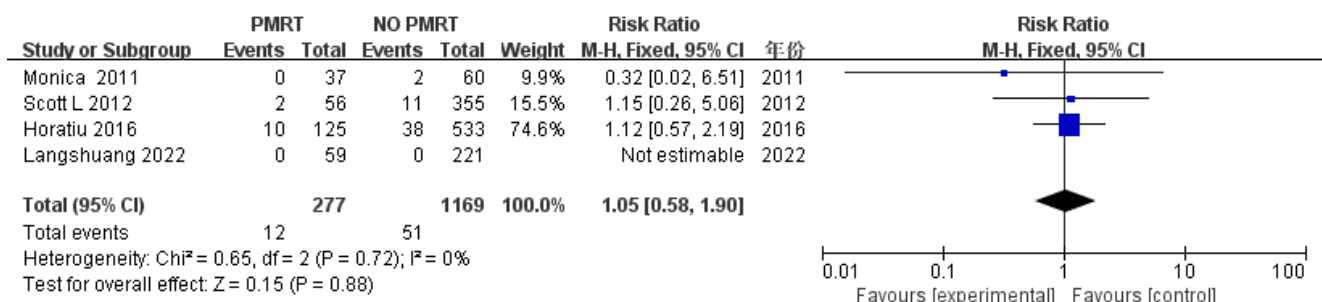


Figure 5. Forest plot for the impact of PMRT on flap necrosis

3.2.5. Exposure

Seven studies were included for heterogeneity testing. The results showed: $I^2 = 61\%$ ($> 50\%$), and Q-test $P = 0.02$ (< 0.1), indicating that the heterogeneity among the included literature was statistically significant and required further exploration. Sensitivity analysis of the seven included studies revealed that Sun *et al.*'s study^[12] had a significant impact on heterogeneity. After excluding this study, heterogeneity testing was conducted again, and the results showed that there was no heterogeneity among the remaining six studies [$I^2 = 45\%$ ($< 50\%$), $P = 0.11$ (> 0.1)]. Only after removing Sun *et al.*'s study^[12] was a fixed-effect model used for analysis. The final meta-analysis results showed that compared to cases that did not receive radiotherapy, cases that received post-reconstruction radiotherapy had a significantly increased risk of implant exposure by 4.13 times (95% CI: 2.68–6.38), and the difference was statistically significant ($P < 0.00001$). Further details are shown in Figure 6.

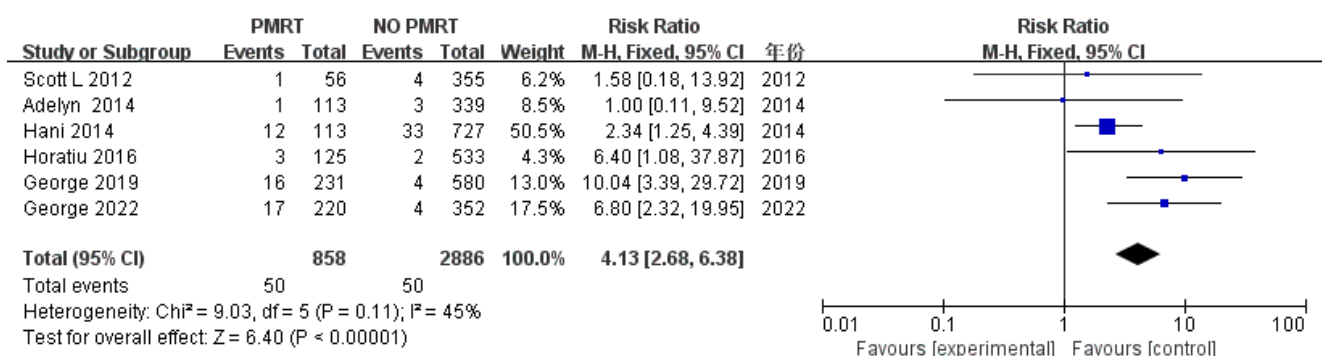


Figure 6. Forest plot for the impact of PMRT on implant exposure

3.2.6. Capsular contracture

Five studies were included for heterogeneity test, and the results showed that $I^2 = 48\%$ ($< 50\%$), and $P = 0.1$ for Q-test, indicating small heterogeneity, and the fixed-effect model was used to combine effect sizes. The results of the meta-analysis showed that the risk of capsular contracture was significantly increased by 3.16 times (95% CI: 2.22–4.48) in patients who received post-reconstructive radiotherapy compared with those who did not receive radiotherapy, and the difference was statistically significant ($P < 0.00001$). Further details are shown in Figure 7.

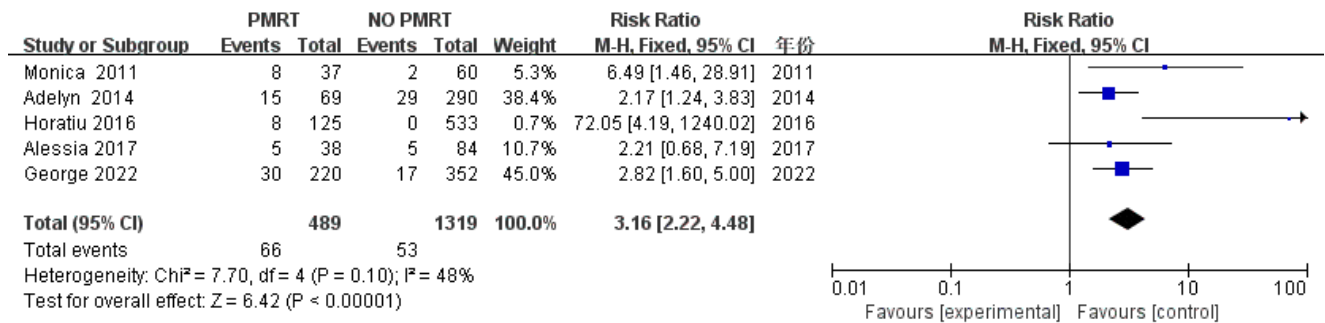


Figure 7. Forest plot for the impact of PMRT on capsule contracture

3.2.7. Reconstruction failure

Eight studies were included for heterogeneity test, and the results showed that $I^2 = 24\%$ ($< 50\%$), and Q-test $P = 0.24$, indicating small heterogeneity, and the fixed-effect model was used to combine effect sizes. The results of the meta-analysis showed that the risk of reconstructive failure was significantly increased by 4.18 times (95% CI: 3.26–5.38) in patients who received post-reconstructive radiotherapy compared with those who did not receive radiotherapy, and the difference was statistically significant ($P < 0.00001$). See the forest map (Figure 8) for details.

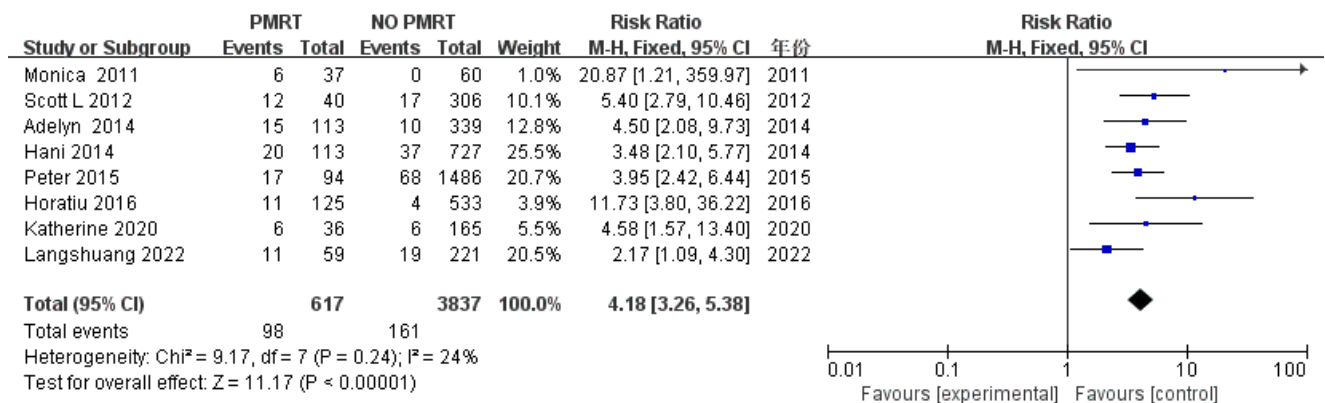
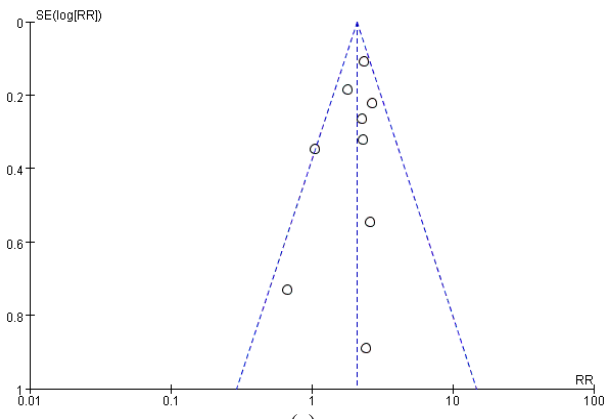


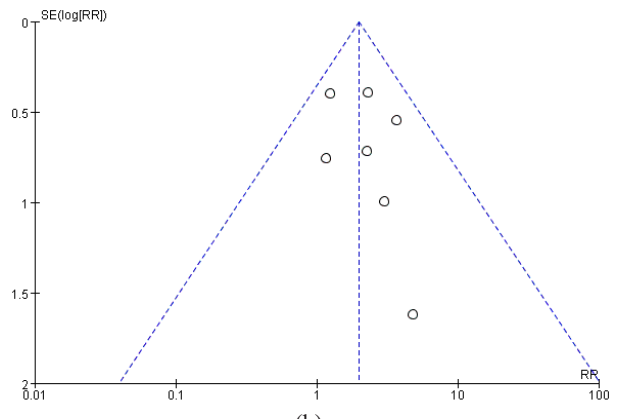
Figure 8. Forest plot for the impact of PMRT on reconstruction failure

3.3. Evaluation of publication bias

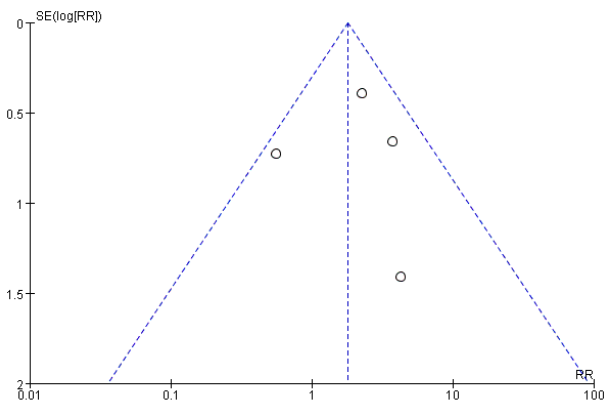
The funnel plot showed a relatively high concentration and basic symmetry in the analysis of seroma, infection, implant exposure, and reconstruction failure, suggesting that publication bias may be low for these outcomes. However, in the analysis of incision dehiscence, flap necrosis, and capsular contracture, there were fewer studies, fewer cases, and noticeable asymmetries, indicating potential publication bias.



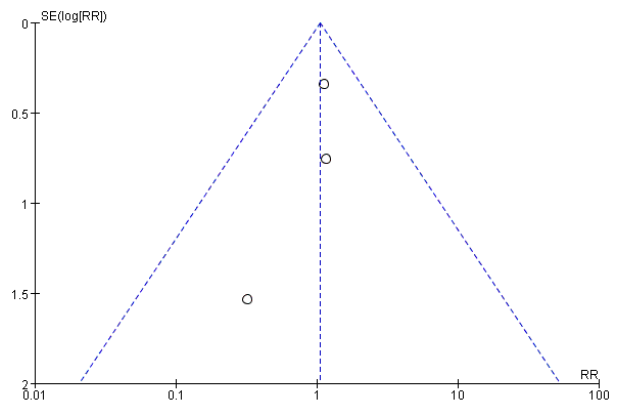
(a)



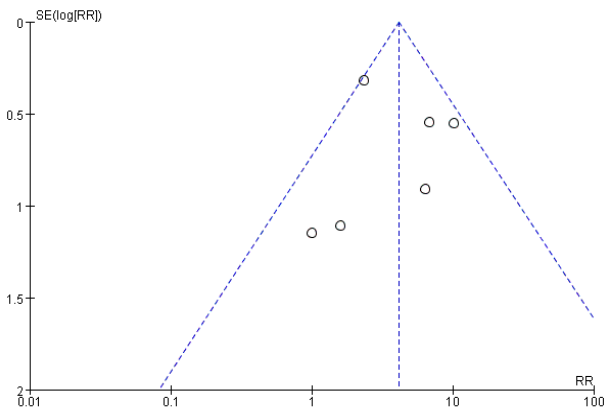
(b)



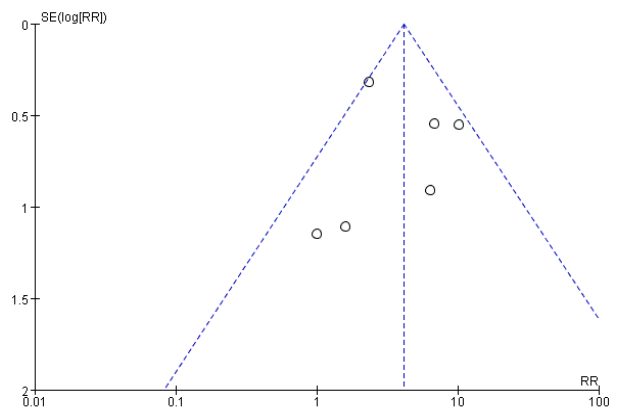
(c)



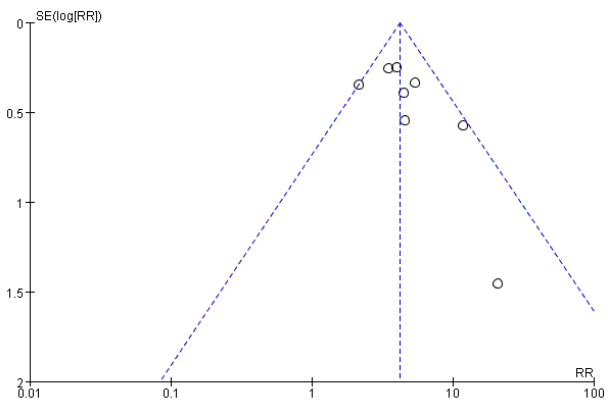
(d)



(e)



(f)



(g)

Figure 9. Funnel plots. (a) Seroma; (b) Infection; (c) Wound dehiscence; (d) Flap necrosis; (e) Implant exposure; (f) Capsule contracture; (g) Reconstruction failure.

4. Discussion

The surgical treatment of breast cancer has been evolving over the last decade, with a growing global trend towards breast reconstruction immediately after mastectomy and breast-conserving surgery. For these women with early invasive breast cancer, plastic surgeons may offer reconstruction as an option^[21]. Immediate reconstruction surgery reduces the psychological trauma and appearance satisfaction of women after mastectomy by restoring the contour of the breast. With the widespread use of radiation therapy, the number of breast cancer patients receiving radiation is increasing, and the survival rate is also improving. Radiation therapy has become an important pillar of treatment for breast cancer. In women with locally advanced breast cancer as well as positive lymph node biopsy^[22], post-mastectomy radiation therapy (PMRT) may reduce the risk of local recurrence and breast cancer death. Despite its therapeutic advantages, PMRT increases the risk of complications and generally has poor cosmetic results for women undergoing breast reconstruction. Immediate reconstruction may affect the implementation of the PMRT program, resulting in increased doses to the heart and lungs^[23]. In delayed breast reconstruction after PMRT, much of the skin at the surgical incision usually develops severe fibrosis, making breast scars more difficult to hide^[24]. However, these problems have been reduced over the past decade by advances in plastic surgery and radiation therapy, which have led to the increasing integration of radiation therapy with breast reconstruction protocols. Minimizing complications without compromising oncology outcomes remains a key goal in the treatment of women who receive immediate reconstruction and who undergo PMRT. A cohort study^[25] of 725 breast cancer patients undergoing implantable immediate breast reconstruction (IBR) found that the 5-year IBR failure rate was estimated to be 10.4% in the non-radiotherapy group and 25.2% in the postoperative radiotherapy group ($P < 0.001$). At least 44% of patients in the group that did not receive radiotherapy had re-surgery, compared with 59% in the group that received postoperative radiotherapy ($P < 0.001$). Radiation therapy significantly increased the rate of reconstruction failure and decreased the rate of BreastQ scores (a standardized assessment tool used to assess the effectiveness and patient satisfaction of breast reconstruction surgery). Lee and Mun^[26] found that compared with the control group, adjuvant radiotherapy resulted in a significantly higher rate of reconstruction failure in immediate two-stage prosthetic breast reconstruction (18.6% v.s. 3.1%, $P < 0.00001$). Radiotherapy after stage 1 (dilators) (29.7% v.s. 5%, $P < 0.00001$) and stage 2 (permanent implants) (7.7% v.s. 1.5%, $P = 0.0003$) in particular increased the failure rate. Severe capsular contracture was also increased in irradiated patients, with less cosmetic results. Ho *et al.*^[16] compared 113 irradiated breasts with 339 unirradiated breasts after immediate two-stage tissue dilator/implant reconstruction and found a 4.2-fold increase in major complications in the irradiated group (OR: 4.2; $P = 0.001$). Compared with the control group, the rate of capsular contracture in grade III and IV was significantly higher in the irradiated group (21.7% v.s. 10%; $P < 0.008$). This is despite these previous studies showing that the use of PMRT leads to significantly higher complication rates in patients undergoing immediate breast reconstruction. In general, however, some researchers^[25,26] consider immediate tissue dilator/implant reconstruction to be a reasonable surgical option in the case of post-mastectomy radiotherapy. Jagsi *et al.*^[27] found that an increased risk of infection was observed in exposed patients who received immediate implant reconstruction only within 7 to 24 months of surgery, but not within the first 6 months of surgery, considering that these infections may not be related to radiation therapy, but to revision surgery performed after completion of radiation therapy Wang and colleagues^[28] followed 776 immediate two-stage dilator/implant reconstruction cases for a median follow-up of 26 months and found that axillary lymph node dissection increased the risk of implant loss compared to sentinel lymph node biopsy, independent of radiation therapy. When possible, patients who require axillary lymph node dissection are encouraged to undergo breast preservation or aut Reconstruction.

For this meta-analysis, 11 well-controlled cohort studies published over the past 15 years were selected,

including a total of 6,323 immediate reconstruction cases. These studies evaluated breast cancer patients who underwent mastectomy and immediate breast reconstruction treatment and compared various complications in patients who received and did not receive PMRT. The results showed that the risk of seroma, infection, incision rupture, and implant exposure in patients receiving reconstructive radiotherapy was significantly increased by 1.77 times, 2.07 times, 1.8 times, and 4.13 times, respectively, compared with those who did not receive radiotherapy, with statistical significance. There was no significant difference in the risk of flap necrosis between the two groups. In addition, we observed a higher incidence of grade III/IV capsular contracture and reconstruction failure in patients undergoing reconstruction with PMRT that required capsulotomy. Based on the evidence from this meta-analysis, we conclude that patients who receive PMRT after immediate breast reconstruction are at a higher risk of various complications than those who do not receive PMRT, but radiation therapy remains the standard of choice for these patients. We recommend that postoperative PMRT is still acceptable. At the same time, our meta-analysis has some limitations. First of all, the literature we included lacked randomized trials and the level of evidence was not enough. Second, we analyzed immediate primary prosthesis and secondary dilator implantation reconstruction together and did not explore the possible influence of radiotherapy timing on complications, although meta-analyses^[28] suggest that there may be no difference in the risk of serious complications, including reconstruction failure. In addition, many of these studies were limited by radiotherapy techniques, doses, and times of exposure.

5. Conclusion

This study found that PMRT in patients undergoing immediate breast reconstruction resulted in a higher risk of seroma, infection, incision rupture, implant exposure, capsular contracture, and reconstruction failure. However, this meta-analysis can help patients understand the comprehensive plan of breast cancer treatment and be consulted about these possible complications before surgery, if necessary, with the help of a doctor to take preventive measures in advance. Due to the lack of well-controlled large-scale studies, we may need further comparative studies to draw more definitive conclusions and provide a basis for future research.

Disclosure statement

The authors declare no conflict of interest.

References

- [1] Sung H, Ferlay J, Siegel RL, et al., 2021, Global Cancer Statistics 2020: GLOBOCAN Estimates of Incidence and Mortality Worldwide for 36 Cancers in 185 Countries. *CA Cancer J Clin*, 71(3): 209–249.
- [2] Arnold M, Morgan E, Rungay H, et al., 2022, Current and Future Burden of Breast Cancer: Global Statistics for 2020 and 2040. *Breast*, 66: 15–23.
- [3] Curigliano G, Burstein HJ, Gnant M, et al., 2023, Understanding Breast Cancer Complexity to Improve Patient Outcomes: The St Gallen International Consensus Conference for the Primary Therapy of Individuals with Early Breast Cancer 2023. *Ann Oncol*, 34(11): 970–986.
- [4] Chen Y, Wu S, 2022, Surgical Treatment of Hereditary Breast Cancer. *Surgical Theory and Practice*, 27(05): 392–395.
- [5] EBCTCG (Early Breast Cancer Trialists' Collaborative Group), McGale P, Taylor C, et al., 2014, Effect of Radiotherapy After Mastectomy and Axillary Surgery on 10-Year Recurrence and 20-Year Breast Cancer Mortality:

Meta-Analysis of Individual Patient Data for 8135 Women in 22 Randomised Trials. *Lancet*, 383(9935): 2127–2135.

- [6] Gradishar WJ, Moran MS, Abraham J, et al., 2023, NCCN Guidelines® Insights: Breast Cancer, Version 4. *J Natl Compr Canc Netw.*, 21(6): 594–608.
- [7] Ilonzo N, Tsang A, Tsantes S, et al., 2016, Breast Reconstruction After Mastectomy: A Ten-Year Analysis of Trends and Immediate Postoperative Outcomes. *Breast*, 32: 7–12.
- [8] Spear SL, Baker JL, 1995, Classification of Capsular Contracture After Prosthetic Breast Reconstruction. *Plast Reconstr Surg*, 96: 1119–1123
- [9] Wells GA, Shea B, O’Connell D, Peterson J, et al., 2021, The Newcastle-Ottawa Scale (NOS) for Assessing the Quality of Nonrandomised Studies in Meta-Analyses, The Ottawa Hospital Research Institute, viewed March 8, 2022, https://www.ohri.ca/programs/clinical_epidemiology/oxford.asp
- [10] Sun L, Zhu W, Zhang J, et al., 2022, The Risk Factors and the Relationship Between Radiation Dose and Complications and Prosthetic Reconstruction Failure in Patients with Post-Mastectomy Breast Implant Reconstruction: A Retrospective Cohort Study. *Gland Surg*, 11(11): 1817–1831.
- [11] Muresan H, Lam G, Cooper BT, et al., 2017, Impact of Evolving Radiation Therapy Techniques on Implant-Based Breast Reconstruction. *Plast Reconstr Surg*, 139(6): 1232e–1239e.
- [12] Chiasson KF, Kumbala PA, Restrepo RD, et al., 2020, Immediate Latissimus Dorsi and Prosthetic Reconstruction in the Setting of Postmastectomy Radiation: An Analysis of 376 Breast Reconstructions. *Ann Plast Surg*, 84(6S Suppl 5): S364–S368.
- [13] Lardi AM, Ho-Asjoe M, Junge K, et al., 2017, Capsular Contracture in Implant Based Breast Reconstruction: The Effect of Porcine Acellular Dermal Matrix. *Gland Surg*, 6(1): 49–56.
- [14] Peter G, Cordeiro, Albornoz CR, McCormick B, et al., 2015, What is the Optimum Timing of Postmastectomy Radiotherapy in Two-Stage Prosthetic Reconstruction: Radiation to the Tissue Expander or Permanent Implant? *Plast Reconstr Surg*, 135(6): 1509–1517.
- [15] Muresan H, Lam G, Cooper BT, et al., 2017, Impact of Evolving Radiation Therapy Techniques on Implant-Based Breast Reconstruction. *Plast Reconstr Surg*, 139(6): 1232e–1239e.
- [16] Drucker-Zertuche M, Bargallo-Rocha E, Zamora-Del RR, 2011, Radiotherapy and Immediate Expander/Implant Breast Reconstruction: Should Reconstruction Be Delayed? *Breast J*, 17(4): 365–370.
- [17] Naoum GE, Ioakeim MI, Shui AM, et al., 2022, Radiation Modality (Proton/Photon), Timing, and Complication Rates in Patients with Breast Cancer Receiving 2-Stages Expander/Implant Reconstruction. *Pract Radiat Oncol*, 12(6): 475–486.
- [18] Ho AL, Bovill ES, Macadam SA, et al., 2014, Postmastectomy Radiation Therapy after Immediate Two-Stage Tissue Expander/Implant Breast Reconstruction: A University of British Columbia Perspective. *Plast Reconstr Surg*, 134: 1e–10e.
- [19] Sbitany H, Wang F, Peled AW, et al., 2014, Immediate Implant-Based Breast Reconstruction Following Total Skin-Sparing Mastectomy: Defining the Risk of Preoperative and Postoperative Radiation Therapy for Surgical Outcomes. *Plast Reconstr Surg*, 134(3): 396–404.
- [20] Naoum GE, Salama L, Niemierko A, et al., 2019, Single Stage Direct-to-Implant Breast Reconstruction Has Lower Complication Rates Than Tissue Expander and Implant and Comparable Rates to Autologous Reconstruction in Patients Receiving Postmastectomy Radiation. *Int J Radiat Oncol Biol Phys*, 106(3): 514–524.
- [21] Jagsi R, Jiang J, Momoh AO, et al., 2014, Trends and Variation in Use of Breast Reconstruction in Patients with Breast Cancer Undergoing Mastectomy in the United States. *J Clin Oncol*, 32(9): 919–926.
- [22] Overgaard M, Hanne MN, Tramm T, et al., 2022, Postmastectomy Radiotherapy in High-Risk Breast cancer Patients Given Adjuvant Systemic Therapy. A 30-Year Long-Term Report from the Danish Breast Cancer Cooperative Group

DBCG 82bc Trial. *Radiother Oncol*, 170: 4–13.

- [23] Ricci JA, Epstein S, Momoh AO, et al., 2017, A Meta-Analysis of Implant-Based Breast Reconstruction and Timing of Adjuvant Radiation Therapy. *J Surg Res*, 218: 108–116.
- [24] Hoejvig JH, Pedersen NJ, Gramkow CS, et al., 2019, Delayed Two-Stage Breast Reconstruction: The Impact of Radiotherapy. *J Plast Reconstr Aesthet Surg*, 72(11): 1763–1768.
- [25] Eriksson M, Anveden L, Celebioglu F, et al., 2013, Radiotherapy in Implant-Based Immediate Breast Reconstruction: Risk Factors, Surgical Outcomes, and Patient-Reported Outcome Measures in a Large Swedish Multicenter Cohort. *Breast Cancer Res Treat*, 142(3): 591–601.
- [26] Lee K-T, Mun G-H, 2017, Optimal Sequencing of Postmastectomy Radiotherapy and Two Stages of Prosthetic Reconstruction: A Meta-Analysis. *Ann Surg Oncol*, 24(5): 1262–1268.
- [27] Jagsi R, Jiang J, Momoh AO, et al., 2015, Complications After Mastectomy and Immediate Breast Reconstruction for Breast Cancer: A Claims-Based Analysis. *Ann Surg*, 263(2): 219–227.
- [28] Wang F, Peled AW, Chin R, et al., 2015, The Impact of Radiation Therapy, Lymph Node Dissection, and Hormonal Therapy on Outcomes of Tissue Expander-Implant Exchange in Prosthetic Breast Reconstruction. *Plast Reconstr Surg*, 137(1): 1–9.

Publisher's note

Bio-Byword Scientific Publishing remains neutral with regard to jurisdictional claims in published maps and institutional affiliations.