

A Case of Choledocholithiasis Complicated by Choledochoduodenal Fistula

Chao Yang, Yuqiao Sun, Guanghua Xie*

Department of Hepatobiliary Surgery, Yanbian University Hospital (Yanbian Hospital), Yanji 133000, Jilin Province, China

*Corresponding author: Guanghua Xie, yyt9508@sina.com

Copyright: © 2023 Author(s). This is an open-access article distributed under the terms of the Creative Commons Attribution License (CC BY 4.0), permitting distribution and reproduction in any medium, provided the original work is cited.

Abstract: Duodenal fistula refers to the pathological channel formed between the duodenum and the hollow viscera of the human body. If it is connected to a single cavity organ, it is a simple duodenal fistula. If it is connected to ≥ 2 and the hollow viscera are connected, it is a complicated internal duodenal fistula, but simple ones are more common. Once a duodenal fistula develops, it establishes a pathological communication between duodenal contents and related organs, resulting in compromised organ function, infections, malnutrition, bleeding, and other detrimental effects. A patient with choledocholithiasis and choledochoduodenal fistula was treated in our hospital. She underwent laparoscopic left hemihepatectomy + laparoscopic choledochojejunostomy and was discharged 4 days after surgery.

Keywords: Choledochoduodenal fistula; Choledocholithiasis; Surgical treatment

Online publication: September 22, 2023

1. Introduction

A 66-year-old female was admitted to the hospital with the main complaint of repeated right upper abdominal cramping accompanied by yellow staining of skin, mucous membrane, and sclera for 13 days. She was admitted to our hospital on September 14, 2022. Anti-inflammation and symptomatic treatment were performed postoperatively, and there was no obvious discomfort. During the 13 days, she had repeated paroxysmal cramps in the right upper abdomen, accompanied by nausea, yellow staining of skin, mucous membranes, and sclera, without skin itching and history of fever. During the course of the disease, she visited a local hospital, and the result of color ultrasound of the liver, gallbladder, pancreas, and spleen indicated common bile duct stones. However, her symptoms did not improve even after the administration of anti-inflammatories, analgesic, antispasmodic and other symptomatic treatments. She was then transferred to our hospital for further treatment.

2. Case analysis

Medical history: She underwent an abdominal cholecystectomy 20 years ago. Admission examination: pronounced yellow discoloration of the skin, mucous membranes, and sclera throughout the body. The abdomen

appeared flat and soft, lacking discernible gastrointestinal patterns or peristaltic waves. Abdominal wall varicose veins were absent, and tenderness was noted in the right upper abdomen. No evident rebound tenderness or muscle tension was observed. The liver and spleen were also assessed. No palpable abnormalities were detected beneath the ribs, and no noticeable masses were felt across the entire abdomen. Murphy's sign was negative, and shifting dullness was also absent. Additionally, bowel sounds were within the normal range., 4-5 times/min. Blood test: white blood cell count was 4.5×10^9 /L, neutrophil percentage was 41.3%, total bilirubin was 11.3 $\mu\text{mol/L}$, direct bilirubin was 3.8 $\mu\text{mol/L}$, indirect bilirubin was 7.5 $\mu\text{mol/L}$, γ -glutamyl transpeptidase was 119 U/L (elevated), alkaline phosphatase was 89 U/L (normal). Magnetic resonance cholangiopancreatography (MRCP): (i) Multiple stones at the lower end of the common bile duct in the extrahepatic and intrahepatic bile ducts accompanied by dilation of the extrahepatic and common bile ducts (the widest part is about 2.9 cm); (ii) Pancreatic duct dilation; (iii) Congenital intrahepatic bile duct dilatation is not ruled out. Admission diagnosis: (i) obstructive jaundice, (ii) extrahepatic and intrahepatic bile ducts, (iii) cystic dilatation of extrahepatic bile ducts, (iv) it was decided that an elective laparoscopic left hemi-hepatectomy + laparoscopic choledochojunostomy would be performed upon cholecystectomy. Blood test after surgery: albumin was 32 g/ L, total protein was 56 g /L, prealbumin was 66 mg/L, lymphocyte percentage was 2.70 %, lymphocyte count was 0.34×10^9 /L, which indicated that the patient was malnourished. other factors were also considered to determine whether the patient was suitable for the surgery. The day before the operation, her symptoms recurred and worsened. She no obvious signs of peritonitis and fever, and the symptoms were relieved after symptomatic treatment. The results of the liver function test in the morning of the next day showed a total bilirubin of 50.0 $\mu\text{mol/L}$ (significantly lower than before), and the direct bilirubin was 35.1 $\mu\text{mol/L}$ (significantly lower than before). It was considered that the severe dilation of extrahepatic and intrahepatic bile ducts caused the stones to migrate into the bile duct, and the obstructive jaundice was temporarily relieved. (**Figure 1** and **Figure 2**)

After routine preoperative preparations, the surgery was performed under general anesthesia on September 19, 2022. The patient was placed in the prone position, and the operation began after the anesthesia took effect. The duodenoscope was inserted into the patient's digestive tract through the mouth.

No evident anomalies were observed in the stomach. The papillary nipple was visible in the descending portion of the duodenum, with the fistula opening positioned above it, measuring about 2.0×3.0 cm. A guide wire was introduced through the incision, extending to the nipple, and both the guide wire and the incision were visible within the fistula tract. It was deduced that the fistula tract has been obstructed by stones near the confluence of the common bile duct and pancreatic duct (ampulla), leading to a perforation into the duodenum, resulting in an endoleak. During the procedure, 30 mL of 30% iohexol was introduced via an incision, facilitating visualization of the intrahepatic and extrahepatic bile ducts. No distinct stone shadow was observed in the lower segment of the common bile duct; however, the common bile duct exhibited dilation, measuring approximately 2.0 cm in diameter. Angiography was performed again, and there was no obvious filling defect in the common bile duct. No obvious active bleeding was observed in the nipple. A 7-Fr nasobiliary catheter was successfully inserted, and the endoscope was withdrawn. Gas and liquid from the gastrointestinal cavity were aspirated during the withdrawal process, ensuring a smooth operation. The drainage functioned effectively, and the patient exited the procedure room without complications. Eating and drinking were prohibited after the operation, and anti-inflammatory treatment was given according to the patient's symptoms (**Figure 3**).

The patient recovered smoothly after the operation, and the postoperative blood test results showed that the total bilirubin was 40.1 $\mu\text{mol/L}$, and the direct bilirubin was 28.3 $\mu\text{mol/L}$. Postoperative abdominal CT results: (i) intrahepatic bile duct dilation and gas accumulation, (ii) small intestine and colon dilation, gas accumulation, and fluid accumulation. Endoscopic retrograde cholangiopancreatography (ERCP) might cause bloating.

Jaundice symptoms notably improved in comparison to the time of admission, and there were no evident complications such as abdominal pain or postoperative pancreatitis. The patient was discharged four days after the surgery; however, follow-up after discharge could not be conducted (**Figure 4**).

3. Discussion

Choledochoduodenal fistula (CDF) refers to the pathological passage between the common bile duct and the duodenum. Symptoms of CDF is similar to those of cholelithiasis, duodenal and gastric ulcer, cholecystitis, and other diseases, so it is difficult to distinguish. Additionally, CDFs are often challenging to detect using routine preoperative ultrasound, CT scans, or MRCP. They are most commonly diagnosed through ERCP.

The anatomical structure of the common bile duct features two physiological strictures: one occurs at the junction where the common bile duct enters the duodenum, and the other is at the duodenal papilla. Repeated stimulation of oppression and chronic inflammatory reactions, or long-term oppression of adjacent organ tumors, can cause damage to the bile duct wall, forming a fistula ^[1]. Another study reported that the common cause of CDF is duodenal ulcer, and the inflammatory reaction of larger ulcers is more severe, causing it to penetrate the duodenal wall and form a fistula with the rear common bile duct ^[2]. In addition, studies have shown that the etiology of CDF is related to iatrogenic or endogenous injuries such as peptic ulcer and duodenal tuberculosis ^[3].

In recent years, the incidence of cholelithiasis has gradually increased with the aging of the population and changes in diet. Since the main cause of CDF is cholelithiasis, the incidence of CDF has also increased ^[4]. CDF is currently classified through Gong Jianping's. Gong *et al.* ^[5] divided CDF into 3 types: type A, the fistula is ≥ 2 cm away from the duodenal papilla; type B, the fistula is < 2 cm from the duodenal papilla; and type C, also known as the common bile duct paraduodenal fistula (PCDF), which opens in the duodenal papilla fold. The classification of CDF is important for clinical diagnosis and treatment, and the location of fistula helps in determining etiology of CDF.

The treatment approach for CDF involves addressing the underlying cause, excising the fistula, providing fixation, and managing associated complications. Depending on classification, the treatment plan can be categorized as follows: (i) For fistulas with a diameter > 1 cm and inner common bile duct diameter > 2 cm, surgical intervention is recommended. (ii) In cases where the fistula diameter is 0.5–1.0 cm and the inner common bile duct diameter is > 1.2 cm, surgical or ERCP options can be considered. (iii) For fistulas with a diameter < 0.5 cm and no complications, conservative treatment may be attempted ^[6].

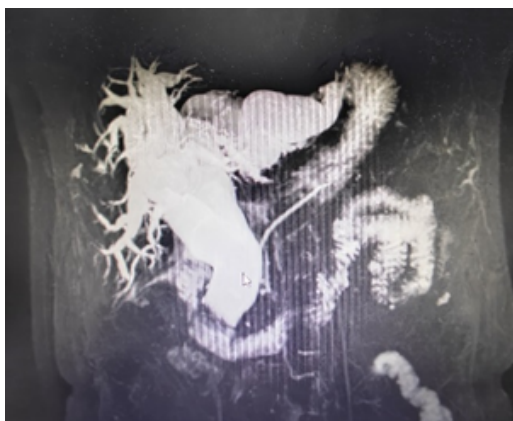


Figure 1. Biliary Tree for MRCP

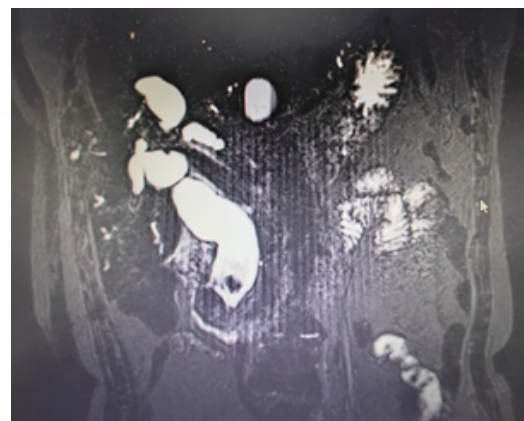


Figure 2. Stones at the end of the common bile duct under MRCP

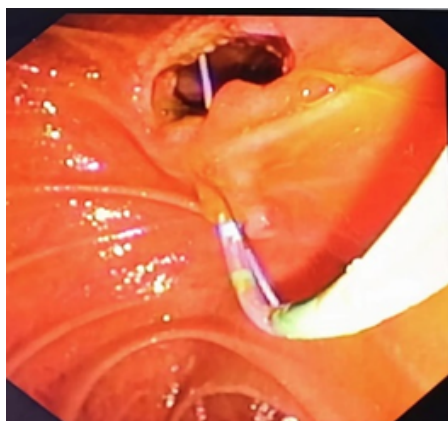


Figure 3. ERCP lower incision knife enters the common bile duct from the large papilla of the duodenum

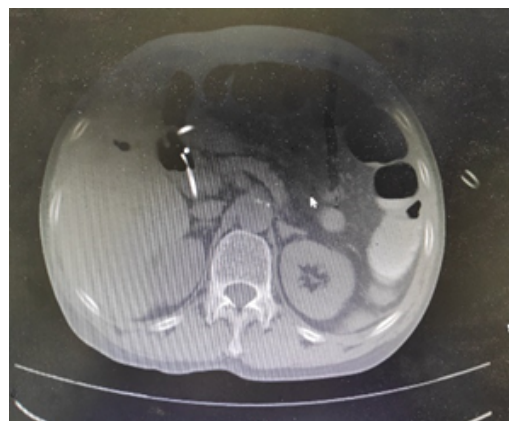

Figure 4. Postoperative CT

4. Conclusion

In conclusion, for patients with prolonged bile duct stones characterized by large single stones or obstructed stones, if there is a rapid and complete relief of pain after sudden exacerbation, along with a significant drop in the bile pigment index, it is crucial to consider the possibility of choledochoduodenal fistula, even if imaging in the days leading up to the operation and clinical evidence suggest bile duct stones and no apparent internal fistula.

Disclosure statement

The authors declare no conflict of interest.

References

- [1] Kachi A, Kanj M, Khaled C, *et al.*, 2019, Choledochoduodenal Fistula Secondary to Peptic Ulcer Disease: A Case Report. *Am J Case Rep*, 20: 398–401.
- [2] Stagnitti F, Stagnitti A, Tarcoveanu E, 2021, Spontaneous Biliary-Enteric Fistulas and Associated Complications: An Overview. *Chirurgia (Bucur)*, 116(6 Suppl): S28–S35.
- [3] Kuang Y, 2004, A Case Report of Gastroduodenal Fistula Caused by Peptic Ulcer. *Journal of Local Surgery*, 13(2): 109.
- [4] Tazuma S, Unno M, Igarashi Y, *et al.*, 2017, Evidence-Based Clinical Practice Guidelines for Cholelithiasis 2016. *J Gastroenterol*, 52(3): 276–300.
- [5] Gong J, Zhou Y, Han B, 1999, Diagnosis and Classification of Choledochoduodenal Fistula. *Chinese Journal of Digestive Endoscopy*, 1999(2): 42–43.
- [6] Li ZH, Ding J, Ye Y, *et al.*, 2006, New Strategy to Prevent Ascending Cholangitis in Larger Choledochoduodenal Fistula. *ANZ J Surg*, 76(9): 796–800.

Publisher's note

Bio-Byword Scientific Publishing remains neutral with regard to jurisdictional claims in published maps and institutional affiliations.