

Right Sub-Axillary Incision for Right Pulmonary Vein Atresia in a Child: A Case Report and Literature Review

Weitao Zhang*, Xinhua Wei, Jintao Zhang, Fengfeng Wang, Qun Li

Department of Children's Heart Center, Fuwai Huazhong Cardiovascular Hospital, Zhengzhou 450000, China

*Corresponding author: Weitao Zhang, 124651007@qq.com

Copyright: © 2023 Author(s). This is an open-access article distributed under the terms of the Creative Commons Attribution License (CC BY 4.0), permitting distribution and reproduction in any medium, provided the original work is cited.

Abstract: Unilateral pulmonary vein atresia (UPVA) in children is a rare disease that is characterized by a recurrent pulmonary infection and hemoptysis in childhood. This paper is a report of a case of pulmonary venous atresia treated by a right sub-axillary incision. Hopefully, more literature can be produced to improve the awareness and treatment level of pulmonary vein atresia.

Keywords: Right sub-axillary incision; Unilateral pulmonary vein atresia; Children; Pulmonary collateral vessels

Online publication: May 30, 2023

1. Introduction

Unilateral pulmonary vein atresia (UPVA) in children is a rare disease that is characterized by recurrent pulmonary infection and hemoptysis in childhood. Adult patients occasionally have chest pain or cough, recurrent pleural effusion, and decreased activity tolerance, and some patients have pulmonary hypertension. Pulmonary venous atresia lacks specific clinical manifestations. The types of pulmonary vein atresia include common cava pulmonary vein atresia, bilateral pulmonary vein atresia, unilateral pulmonary vein atresia, and single pulmonary vein atresia. UPVA can be on the left or right side, and there is no reports on which side is more prone to UPVA ^[1]. There is currently no standard clinical treatment for pulmonary vein atresia, and if patients are not treated in time, the long-term case fatality rate is high ^[2]. This paper is a report of a case of pulmonary venous atresia treated by a right sub-axillary incision. Hopefully, more literature can be produced to improve the awareness and treatment level of pulmonary vein atresia.

2. Case presentation

The child was 3 years and 2 months old, weighed 13.5 kg, and admitted to the hospital with SpO₂ of 97%. He was hospitalized with the chief complaint of "intermittent cough and fever for more than one month." Children with pulmonary atresia usually have heavier breathing, poor physique, and sweating and are prone to repeated pneumonia. There was no obvious cyanosis and no history of operations or allergies in the past. Physical examination upon admission showed that the patient's breath sounds were rough, the respiratory rate was 30 times/minute, there was no cyanosis of lips, intermittent fever, and the child's peak temperature was 39.0 °C. No pathological murmur was heard in the auscultatory areas of the heart, the breath sounds in the right lung were softer than the left lung, and no dry and wet rales were heard. Echocardiography showed that the right pulmonary vein was not detected, cardiac catheterization was recommended, and systemic

and pulmonary collaterals were formed near the diaphragm on the posterior wall of the right atrium. The chest anteroposterior radiograph showed a large high-density shadow in the right lung, the heart shadow deviated to the right, and the mediastinum was shifted to the right (**Figure 1**). Cardiac CT showed that the development of the right pulmonary artery and its branches was normal, and no right pulmonary venous return was found. The left pulmonary artery was dilated, and the left pulmonary venous return was normal (**Figure 2**). Cardiac catheterization and pulmonary angiography showed that the diameter of the right pulmonary artery was 7.5 mm, the pressure of the right pulmonary artery was 23/15/17 mmHg, the diameter of the left pulmonary artery was 12 mm, and the pressure of the left pulmonary artery was 18/14/15 mmHg. The systolic pressure of the right pulmonary artery was 5 mmHg higher than that of the left pulmonary artery, and the mean pressure was 2 mmHg higher. However, there was no pulmonary hypertension. Pulmonary arteriography showed that the right pulmonary artery was poorly developed with thin branches; no clear development of the right pulmonary vein was found, the emptying of contrast medium was delayed, and the contrast medium could flow back into the left pulmonary artery from the right pulmonary artery. Embedding angiography of the right pulmonary artery revealed the presence of a common trunk and branches of the right pulmonary vein, which was thinly developed and had a delayed emptying of contrast (**Figure 3**). Descending aortography showed the formation of systemic and pulmonary collateral vessels. The systemic and pulmonary collateral vessels were occluded with coils during cardiac catheterization (**Figure 4**). The patient required surgery, and after communication with his family, the patient and his family opted for surgery, including a right axillary incision and right pulmonary vein, and left atrial connection under extracorporeal circulation. During surgery, the right lung was found to be hypoplastic, and there were many enlarged veins on the surface of the lung and pericardium. The junction of the superior and inferior veins of the right lung and the left atrium was atresia, showing a fibrous cord-like atresia without blood flow. The aortic atresia was longitudinally incised, and the pericardial patch of the right pulmonary vein and left atrium was enlarged to restore the blood flow from the right pulmonary vein to the left atrium. Intraoperative ultrasound showed that the flow velocity at the junction of the right pulmonary vein and left atrium was 1 m/s. The patient fully recovered after the operation, and his physique was better than before. Echocardiography and cardiac CT showed that the blood flow of the right pulmonary vein and left atrium was unobstructed, and the patient was discharged. The patient is still undergoing long-term follow-up.

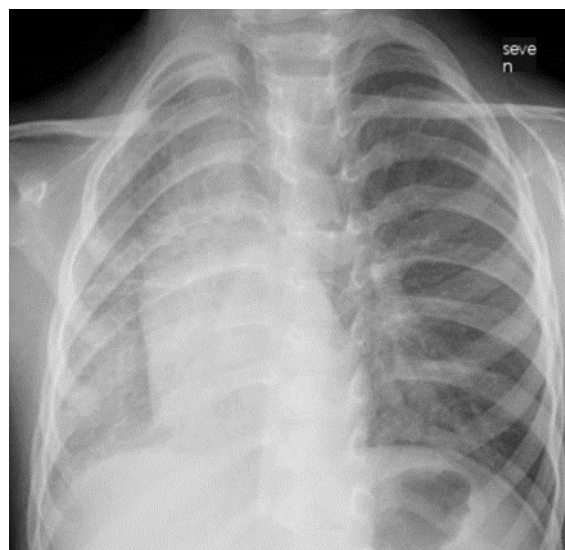


Figure 1. Chest X-ray. Note: The patient's right thorax was slightly smaller, the mediastinum was shifted to the right, the right lung markings were thickened, and the heart shadow was to the right.

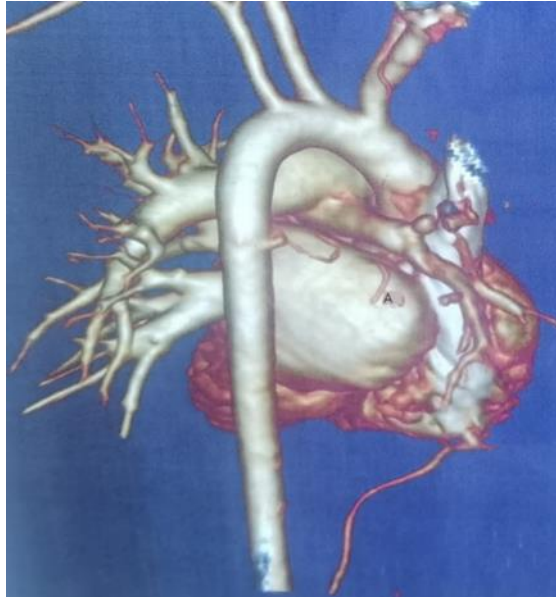


Figure 2. CT three-dimensional reconstruction of the heart of the child. Note: The right pulmonary artery of the patient is narrow, the branches of pulmonary vessels are sparse, the connection between the right pulmonary vein and the left atrium was not seen, and systemic and pulmonary collateral vessels formed in the descending aorta.

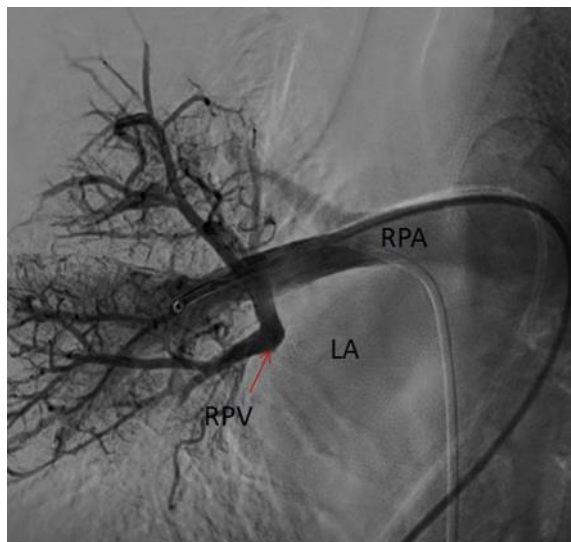


Figure 3. Embedding angiography of the patient's right pulmonary artery. Note: The right pulmonary artery was sparsely marked, the junction of the right pulmonary vein and the left atrium was atretic, and the diffusion of the contrast agent was delayed.

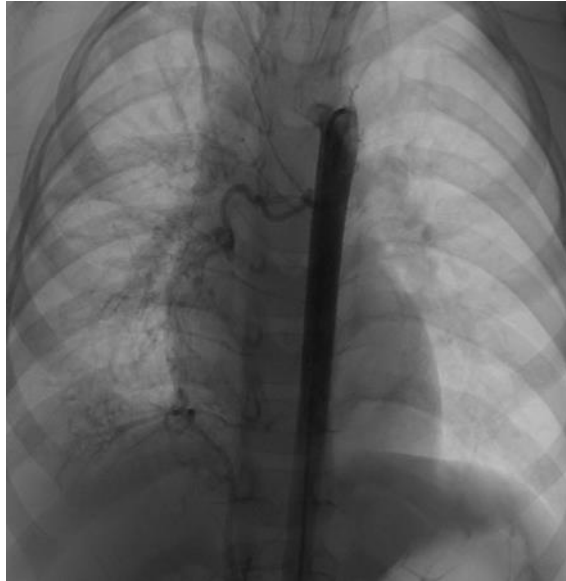

Figure 4. Patient aortography. Note: Angiography of the descending aorta showed the formation of two pulmonary collateral vessels, both supplying the right lung tissue, which were occluded with coils during the operation.

3. Discussion

3.1. Etiology

UPVA is a rare disease, and its morbidity is unknown. At present, most UPVA cases are individual case reports. Fifty percent of the cases occur without any other concurrent conditions, and the remaining 50% of the cases are associated with congenital heart disease^[3]. Pulmonary venous atresia can occur on the left or right side, and although it is usually unilateral, there is no significant site advantage. At present, UPVA is considered to be the main cause of congenital diseases. Most patients develop symptoms at a young age of 2 years old, when the probability of congenital heart disease is higher. Histological evidence of active inflammation is rare in cases of UPVA. Har-Even Cohn *et al.*^[4] reported that three patients with left pulmonary dysplasia and hemoptysis were diagnosed with rare familial UPVA. It was thought that this disease might be related to autosomal dominant inheritance, but the family refused to undergo genetic testing. However, some scholars believe that UPVA is a secondary vascular occlusion change, and the causes of secondary UPVA include postoperative complications of congenital heart disease^[5], mediastinal tumor, pericardial or mediastinal infection, cardiac tumor, and thrombosis. Mohammed Firdouse *et al.*^[6] reported a case where a child had a normal pulmonary artery and pulmonary vein before examination, but UPVA was found during follow-up. The patient had not undergone surgery because there were no obvious clinical manifestations. Right pulmonary vein atresia was found in this patient, along with recurrent pneumonia; right pulmonary hypoplasia was found during the operation; and the right pulmonary artery was more underdeveloped than the left pulmonary artery. The patient had no previous history of surgery, which excludes the possibility of a secondary occlusion. More research would be needed to determine whether it was a repeated infection that led to UPVA. Therefore, it is unclear whether UPVA is a congenital disease, and further study is needed.

3.2. Clinical manifestations

Unilateral pulmonary vein atresia has no specific clinical manifestations. Patients usually show different degrees of clinical signs and symptoms, ranging from repeated pulmonary infection, exertional dyspnea, and hemoptysis to no symptoms at all. Pulmonary hypertension may occur in only some patients, and a case report from the United States was the first to report that a 16-year-old patient did not have concurrent pulmonary hypertension^[7]. The initial symptoms of UPVA are easily misdiagnosed as tuberculosis or

secondary malignant tumors of the lung. In Vietnam, Cung-Van Cong et al. [8] reported that a 19-year-old patient had been misdiagnosed with tuberculosis and was treated for tuberculosis without laboratory evidence. Hemoptysis is caused by the rupture of bronchial varices or the systemic and pulmonary collaterals, which often indicates that the condition is serious and there is a higher possibility of resection of the affected lung. Some patients may not have obvious clinical signs or symptoms, and only occasional chest pain in a patient can allow for a definite diagnosis [7].

3.3. Diagnosis

The gold standard of clinical diagnosis of unilateral pulmonary vein atresia is cardiac catheterization and angiography. The contrast medium of the pulmonary vein would show that blood cannot flow back into the left atrium and that emptying is delayed. Chest antero-posterior radiography may show mediastinal displacement, lung dysplasia on the affected side, thickening of lung markings, and patchy shadows. The chest CT and echocardiography results showed that there was no blood flow between the pulmonary veins and the left atrium. Some patients were complicated with congenital heart disease. Submucosal bronchial varices in the affected lung can be observed through bronchoscopy, which is a definite manifestation of unilateral obstruction of pulmonary venous return [9]. Bronchial varices may not be present if the patient has other bulky collateral pathways. Therefore, bronchial varices should be considered a possibility in cases of UPVA.

3.4. Treatment

At present, there are no clear treatment guidelines or mature treatment plans. It has been reported that some patients had no obvious symptoms and were followed up for a long time [1,7,8]. If the patient has repeated pulmonary infections and hemoptysis and is older at the time of diagnosis, pneumonectomy on the affected side is helpful to improve the quality of life [4,10]. It is believed that cardiac catheterization and angiography should be performed to evaluate the development of the pulmonary veins and the distance between the obturator end of pulmonary veins and the left atrium. There are surgical options such as noncontact suture of pulmonary veins and left atrium or expanded anastomosis of patches, which is selected based on the patient's condition. For patients with hemoptysis, interventional occlusion of collateral vessels can be considered to alleviate the symptoms of hemoptysis to improve their quality of life. In this case, right axillary incision was chosen to anastomose the right pulmonary vein with the left atrium, which had a clear field of vision, minimized the surgical trauma, and made the axillary incision more concealed and beautiful, and this method had not been reported in previous literature.

3.5. Conclusion

UPVA is a rare disease. Whether it is a congenital disease or acquired disease remains debatable. It is important to raise awareness for patients with repeated pulmonary infection and hemoptysis, especially infants, to avoid a missed diagnosis or misdiagnosis. Early detection, definite diagnosis, and appropriate treatment are helpful for the long-term prognosis of patients.

Disclosure statement

The author declares no conflict of interest.

References

- [1] Biradar B, Sharma A, Malhi AS, et al., 2018, Unilateral Pulmonary Vein Atresia: Diagnostic Dilemma Unfolded on Imaging. *BMJ Case Rep*, 2018: bcr2017224154. <https://www.doi.org/10.1136/bcr-2017->

- [2] Patil PP, 2017, Right Pulmonary Venous Atresia: A Rare Cause for Recurrent Unilateral Pneumonia. *J Clin Diagn Res*, 11(9): SD01–SD02.
- [3] Heyneman LE, Nolan RL, Harrison JK, et al., 2001, Congenital Unilateral Pulmonary Vein Atresia-Radiologic Findings in Three Adult Patients. *AJR Am Roentgenol*, 177(3): 681–685.
- [4] Har-Even Cohn R, Hicks M, Lacson A, et al., 2020, Left Hypoplastic Lung and Hemoptysis-Rare Familial Unilateral Pulmonary Vein Atresia. *Clin Case Rep*. 8(9): 1698–1703.
- [5] Latson LA, Prieto LR, 2007, Congenital and Acquired Pulmonary Vein Stenosis. *Circulation*, 115(1): 103–108. <https://www.doi.org/10.1161/CIRCULATIONAHA.106.646166>
- [6] Firdouse M, Agarwal A, Grosse-Wortmann L, et al., 2015, Acquired Unilateral Pulmonary Vein Atresia in a 3-Year-Old Boy. *J Ultrasound* 18: 73–78. <https://doi.org/10.1007/s40477-014-0135-0>
- [7] Hackett G, Stefek B, Weber H, 2021, Incidental Finding of Congenital Unilateral Pulmonary Vein Atresia During Work-Up for Non-Specific Chest Pain. *Journal of the American College of Cardiology*, 77(18S1): 2751
- [8] Cong CV, Ly TT, Duc NM, 2022, Unilateral Pulmonary Vein Atresia: Literature Overview and Case Report. *Radiol Case Rep*, 17(4): 1313–1317.
- [9] Tissot C, Corbelli R, Aggoun Y, et al., 2008, Bronchoscopic Diagnosis of Asymptomatic Unilateral Pulmonary Vein Atresia in an Infant. *Pediatr Cardiol*, 29(5): 976–979.
- [10] Dell’Amore A, Campisi A, Congiu S, et al., 2018, Unilateral Pulmonary Vein Atresia Without Anomalous Connection in Adult Patient with Recurrent Severe Hemoptysis. *J Vis Surg*, 4: 111.

Publisher’s note

Bio-Byword Scientific Publishing remains neutral with regard to jurisdictional claims in published maps and institutional affiliations.