

A Case of Colon Cancer Surgery Complicated with Acute Myocardial Infarction

Fang Huang¹, Sicong Yang², Yang Wu², Kaiyu Tang², Wencong Yang^{3*}

¹The University of Hong Kong-Shenzhen Hospital, Shenzhen 518053, Guangdong Province, China

²The Seventh Affiliated Hospital, Sun Yat-sen University, Shenzhen 517108, Guangdong Province, China

³Dongguan First Hospital Affiliated to Guangdong Medical University, Dongguan 523121, Guangdong Province, China

*Corresponding author: Wencong Yang, huangfang_syssz@163.com

Copyright: © 2022 Author(s). This is an open-access article distributed under the terms of the Creative Commons Attribution License (CC BY 4.0), permitting distribution and reproduction in any medium, provided the original work is cited.

Abstract: *Objective:* To investigate the treatment and prevention of acute myocardial infarction after colon cancer surgery. *Methods:* A patient with acute anterior myocardial infarction who underwent stent implantation in the Seventh Affiliated Hospital, Sun Yat-sen University in 2017 was selected as the subject. The patient was admitted to the emergency department for stent implantation and took antiplatelet and lipid regulating drugs orally on time after the operation. The patient also had a history of colon cancer. The lesion was resected, and the complication after operation was acute myocardial infarction. After active and effective treatment and intervention, the treatment effect of the patient was analyzed. *Results:* Urgent PTCA was performed, and 0.5 mg Tirofiban was injected into the coronary artery. The results of angiography showed that the blood flow of anterior descending branch recovered to grade 2. *Conclusion:* The condition of patients with myocardial infarction after colon cancer surgery changes rapidly. Surgery combined with drug treatment can achieve a good prognosis, reduce mortality, and improve patients' cardiac function.

Keywords: Colon cancer; Acute myocardial infarction; Treatment method; Prevention method; Functional level

Online publication: November 30, 2022

1. Introduction

Colon cancer is a common digestive tract malignant tumor in the colon, which usually occurs at the junction of rectum and sigmoid colon [1-3]. Previous studies have shown that colon cancer is commonly seen in people aged 40-50, and the incidence of it among men is slightly higher than that of women; and its incidence is the third highest among gastrointestinal tumors. Colon cancer is mainly divided into adenocarcinoma, undifferentiated cancer, and mucinous adenocarcinoma. The clinical manifestations after onset are mostly abdominal distension, indigestion, and mucous stools, which affect the normal lives and health of patients. Surgical treatment is a common intervention method for patients with colon cancer. With the help of surgery, the targeted tissue can be removed, the lives of patients can be prolonged, and the clinical mortality can be reduced. However, surgical treatment is an invasive operation, with a frequent incidence of postoperative complications. Acute myocardial infarction (AMI) is the most serious type of complications after abdominal tumor surgery, and its incidence and mortality are both remarkably high. Therefore, effective measures to prevent AMI clinically is of great significance to improve the prognosis of patients [4-6]. In this study, the clinical data of a patient with AMI after abdominal surgery admitted to our hospital is reported as follows.

2. Materials and methods

2.1 Clinical data

The patient, male, 60 years old, underwent stent implantation for acute anterior myocardial infarction in The Seventh Affiliated Hospital, Sun Yat-sen University in 2017. Antiplatelet and lipid regulating drugs were taken orally on time after the operation. Due to lower abdominal pain for more than 2 months, he was admitted to the digestive disease center of our hospital on October 18, 2019. Relevant examinations were performed before operation, including colonoscopy, electrocardiogram (ECG), echocardiography, and coronary computed tomography angiography (CTA). The examination results are as follows (**Figure 1**, **Figure 2**, and **Figure 3**).

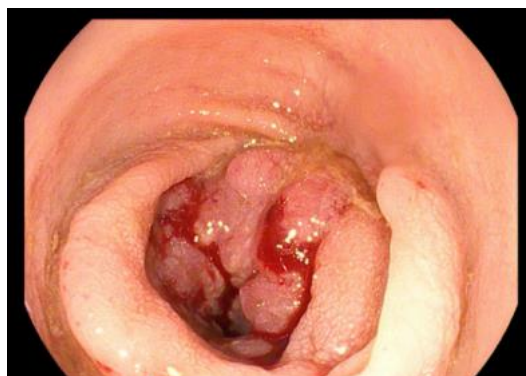


Figure 1. Colonoscopy results

Complete relevant preoperative examinations after admission:

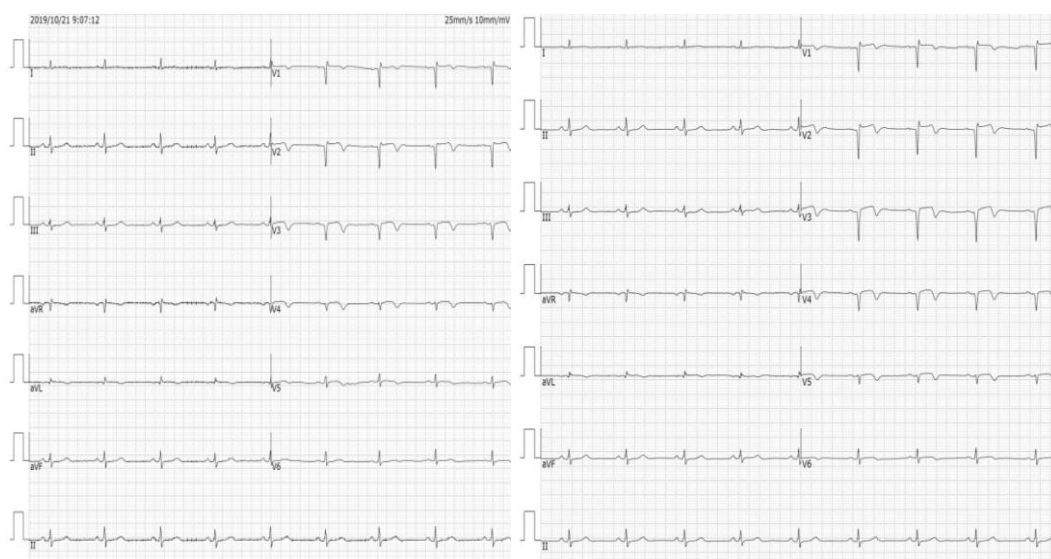

Figure 2. Preoperative ECG examination results

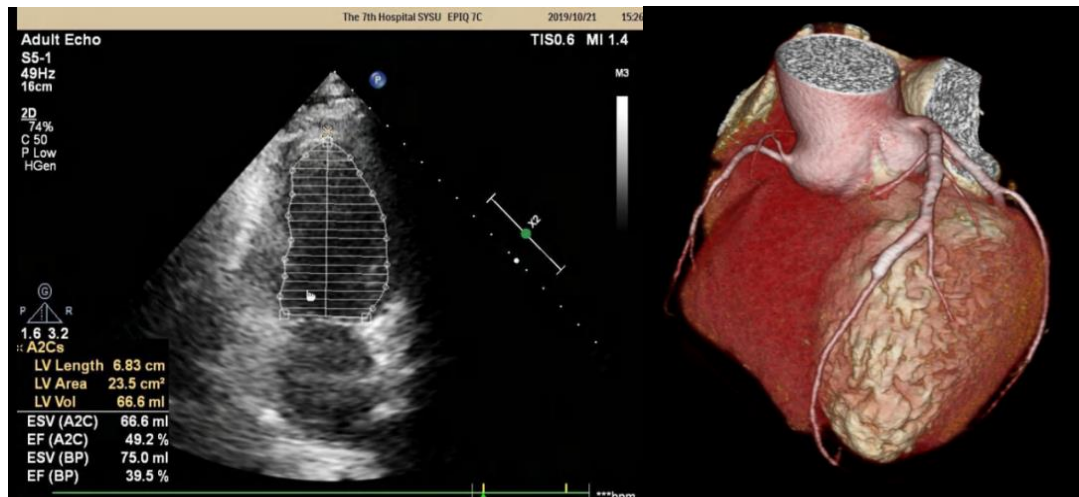


Figure 3. Preoperative echocardiography and coronary CTA examination results (October 21, 2019)

Coronary CTA: The total coronary calcium score was zero, and the left coronary artery was dominant. The changes of proximal-middle segments of left anterior descending coronary artery after stent placement were observed — Coronary Artery Disease - Reporting and Data System (CAD-RADS) showed that there was no stenosis in the three vessels and no stenosis in the stent. Based on the above examination results, the preoperative diagnosis was further clarified: Colon cancer, coronary heart disease, old anterior myocardial infarction, and NYHA class I [7-10].

In order to improve the symptoms of the patient and reduce the clinical mortality rate, a laparoscopic radical resection of left colon cancer was successfully performed under general anesthesia. After the operation, the patient was transferred to the intensive care unit (ICU) for monitoring and treatment. No chest distress or chest pain was observed in the patient. ECG and CTA examinations were performed after the operation. The results are shown in **Figure 4**.

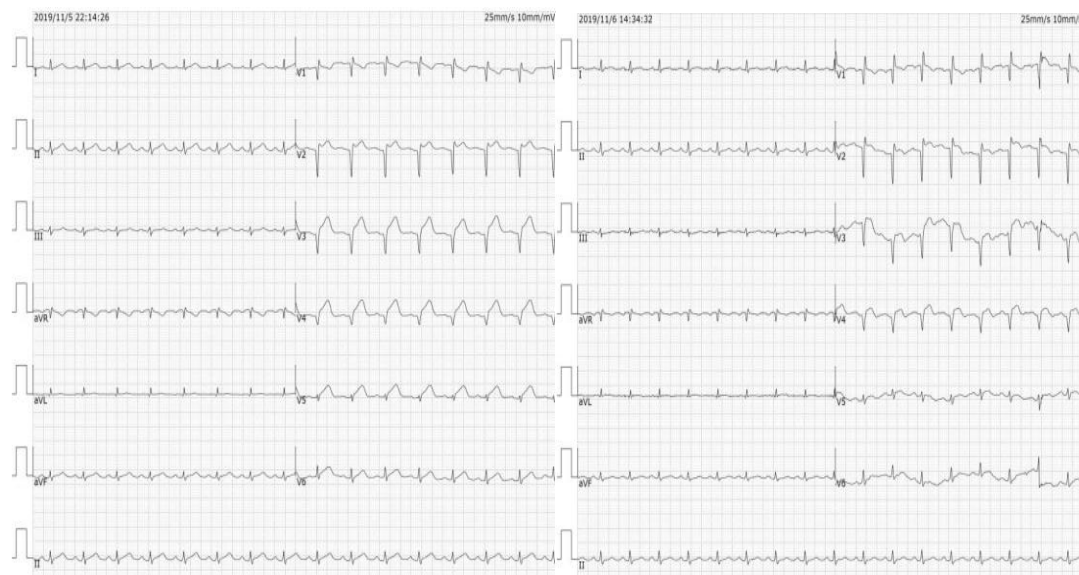


Figure 4. Postoperative ECG results

3. Results

The operation was uneventful, but critical values were received from the laboratory department after the operation: Troponin I (cTn-I) was 5.4934 ng/ml. Combined with the changes in ECG, the patient was

considered to be experiencing AMI. Emergency coronary angiography showed that the lumen of the right coronary artery was small, scattered plaques were seen in the whole process, and no obvious stenosis was found; there was no obvious stenosis in the left main (LM) and opening. Stent shadow could be seen from proximal to distal left anterior descending (LAD) artery, and intimal hyperplasia was seen in the stent. Diffuse severe restenosis could be observed in the proximal stent, with a stenosis rate of about 80%. The middle and distal stents of the anterior descending branch were completely occluded after D2 is branched off. Thrombolysis in myocardial infarction (TIMI) blood flow was grade zero. The proximal segment of D1 showed diffuse severe stenosis, with a stenosis rate of about 90%. LCx was thick. No obvious stenosis was found in the main and branches, and the distal TIMI blood flow was grade 3 [11-14].

PTCA records: After the MINI TREK 2.0*12 mm balloon pre-dilation was performed at the LAD occlusion, the angiography showed that the blood flow at the distal segment of the anterior descending branch restored to grade 2. After that, the patient had a transient hypotension, with the blood pressure decreasing to 50/30 mmHg, and the heart rate increased to 160 beats per min. The reexamination of angiography showed that the blood flow at the distal segment of the anterior descending branch was grade zero, and the blood pressure restored to 1/60 mmHg after intravenous pumping of dopamine. Then, TREK 2.5*12 mm pre-dilated balloon was used to dilate the LAD occlusion repeatedly at 8-12 atm, and 0.5 mg tirofiban was injected into the coronary artery. The following angiographic results showed that the blood flow of the anterior descending branch recovered to grade 2. Postoperative conditions: Body temperature, 36.6 °C ; pulse, 104 beats/min; respiration, 22 times/min; blood pressure, 1/62 mmHg (dopamine 5 ug/kg/min). Unfractionated heparin was given subsequently, anticoagulant was pumped intravenously at 5 U/h, the ACT was monitored and maintained for about 250 s. (**Figure 5, Figure 6, and Figure 7**)

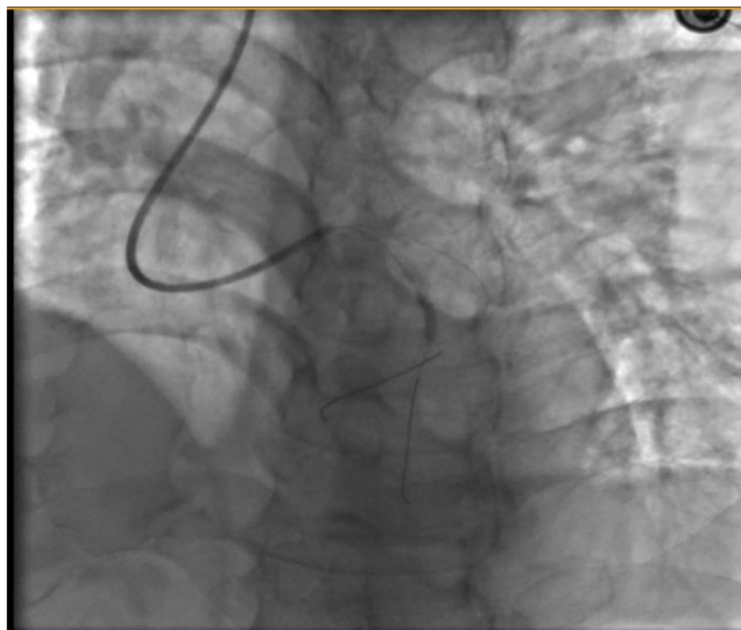


Figure 5. Coronary angiography results

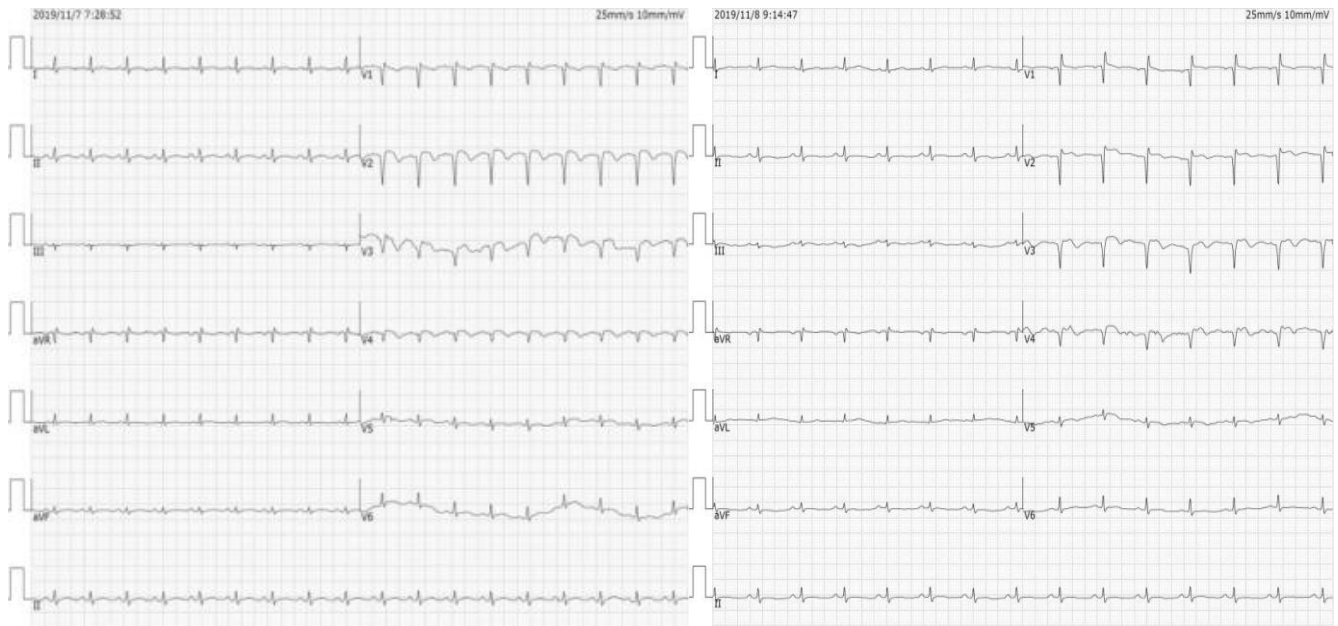

Figure 6. Postoperative ECG

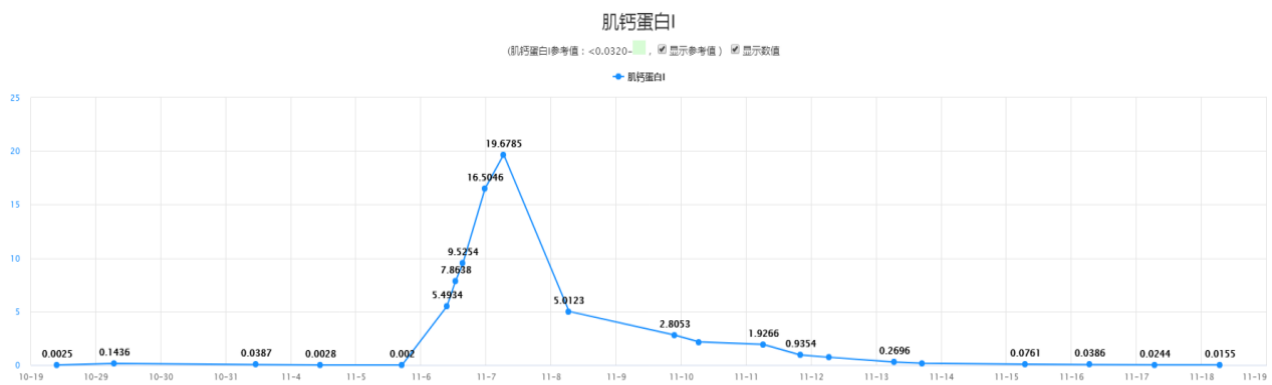


Figure 7. Troponin levels

Translations: 肌钙蛋白 I, Troponin I; 肌钙 I 参考值, Troponin I reference value; 显示参考值, Display reference value; 显示数值, Display value

The patient was reexamined in March 2020 after treatment. The results of ECG and coronary angiography showed that he recovered well. The results are as follows (Figure 8 and Figure 9).

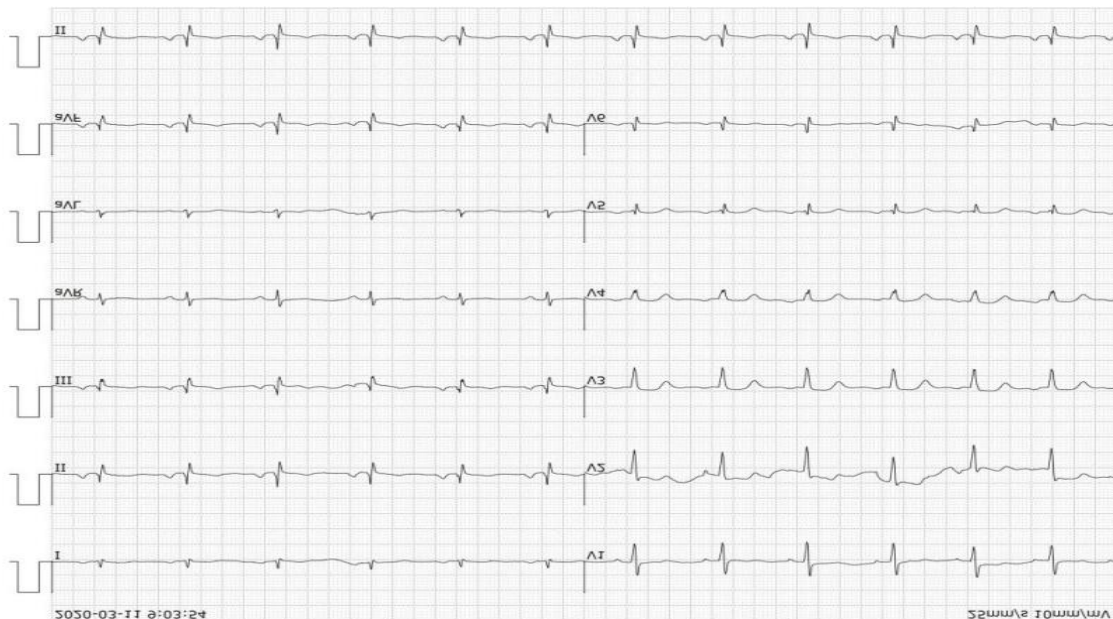

Figure 8. ECG results

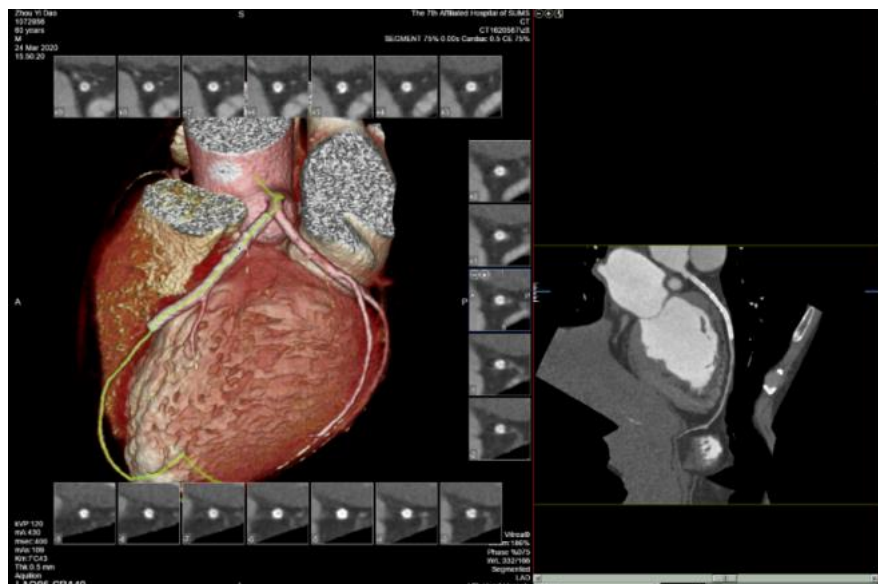

Figure 9. Coronary CTA results

4. Discussion

4.1. Causes of AMI after colon cancer surgery

ECG examination has become a routine item for patients undergoing elective surgery. Even if they are normal before operation, postoperative AMI still occurs from time to time, and is especially more common among the middle-aged, the elderly, and those who have a history of coronary heart disease or risk factors before operation. At present, the strengthening of observation and monitoring of the cardiovascular system after surgery is increasingly being valued by clinicians. In particular, the popularization of ICU provides an important place and means for early detection and effective treatment of combined AMI after surgery. In this case, ECG was performed in time after surgery, but myocardial infarction was not recognized^[15-16]. After a major surgery, patients are often in a state of stress, with increased sympathetic secretion, anesthesia, pain caused by trauma, and the use of vasoactive drugs during surgery, the routine use of postoperative hemostatic drugs, and the effects of hypoxia, blood pressure variability and shock, which often lead to

coronary spasm, or/and there is a greater risk of complicated AMI after surgery than in general patients with simple AMI. They often lack typical clinical manifestations. Due to the use of strong painkillers after operation, gastrointestinal symptoms caused by primary disease or after operation, shock not relieved before and during operation, postoperative fever, and other symptoms can easily overlap with or cover up the symptoms of AMI, resulting in missed diagnosis or misdiagnosis in clinical diagnosis. Especially in the absence of monitoring and doctors' attention, it is more harmful, which is related to the occurrence of AMI in this case. Therefore, for those unexplained shock, hypotension, dyspnea, tachycardia, arrhythmia, and other symptoms that appear or are complications after surgery, we should be highly alert to the possibility of AMI. If possible, routine ECG follow-up observation or ECG monitoring should be carried out. The World Health Organization (WHO) believes that the sequence changes of myocardial enzyme activity are of great significance to the diagnosis of AMI. Therefore, routine or continuous detection of myocardial enzymes in middle-aged and elderly patients after surgery is conducive to early detection of AMI. Although the myocardial enzyme activity will be slightly impacted after a major surgery, it is not difficult to identify AMI in combination with clinical manifestations and characteristic ECG changes. In particular, it is more important to monitor troponin if possible. In this case, the levels of myocardial enzymes were not checked in time, the elevation of which was found the next day.

4.2. Preventive measures for AMI after abdominal surgery

The causes of AMI after abdominal surgery are very complex and often interact with each other. Trauma and stress are the main causes. Hypovolemia caused by blood loss, hypoxia, infection, acidosis, etc. can affect myocardial function and induce AMI. Clinical experience shows that a strict grasp of surgical indications and removal of incentives can minimize postoperative AMI [17-18].

(1) Preoperative prevention

The medical histories of patients should be known and a comprehensive physical examination should be carried out before operation. For patients with coronary heart disease and myocardial ischemia, preoperative preventive measures can significantly reduce the possibility of postoperative AMI. These measures include correct application of antihypertensive drugs to adjust blood pressure to an appropriate range, avoiding tachycardia to increase myocardial oxygen consumption, and eliminating AMI induced by mental tension and emotional excitement.

(2) Intraoperative prevention

During surgery, sufficient oxygen is required for anesthesia, and the oxygen saturation should be maintained above 98%. The frequency and time of iatrogenic hypotension should be minimized. The operation should be suspended during hypotension to correct hypotension and improve myocardial oxygen supply. The surgical methods for elderly patients should be carefully selected. The ideal surgical method should be rapid, effective, and simple. Intraoperative hypertension and tachycardia should be prevented so as to not increase the burden on the heart. Intraoperative blood loss should be minimized, because rapid loss of large amounts of blood can lead to hypotension, and cardiac hypoxia can easily induce AMI.

(3) Postoperative prevention

Postoperative AMI mostly occurs within 7 days after surgery, most of which occur on the second day. Therefore, it is very important to carefully monitor elderly patients for 48–72 hours after the operation and deal with the incentives of AMI in time. The following measures should be taken to prevent AMI: Fully relieve pain and avoid high fever and shivering to reduce oxygen consumption; give adequate oxygen to avoid hypoxemia; prevent pulmonary complications; and prevent and promptly deal with urinary retention and constipation. The elderly people are susceptible to infectious diseases due to low immune function, and infection is the main predisposing factor for the occurrence of AMI in the elderly.

The increase of myocardial oxygen consumption during infection aggravates the imbalance between myocardial oxygen supply and oxygen demand. Infection can cause electrolyte disturbances and acidosis, which can inhibit myocardial contractility. In severe infections, when the pituitary gland releases β -endorphin at a high concentration, it can inhibit the cardiovascular system and induce AMI. Therefore, prevention and control of infection is an important part of preventing postoperative AMI. Patients with postoperative AMI often have no chest pain. After the operation, if a patient has hypotension, arrhythmia, or cardiac insufficiency, which cannot be explained by other reasons, AMI should be considered in the patient. A full-lead ECG and serum enzyme examination should be performed immediately for timely diagnosis and treatment [11,19].

5. Conclusion

In conclusion, the condition of patients with myocardial infarction after colon cancer surgery changes rapidly. Surgery combined with drug treatment can achieve a good prognosis, reduce mortality, and improve patients' heart function.

Disclosure statement

The author declares no conflict of interest.

References

- [1] Diao H, Ni Z, Wang S, et al., 2020, Effect of Component Separation Technique on Abdominal Wall Defect After Abdominal Wall Tumor Resection. *Chinese Journal of General Surgery*, 35(6): 463–467.
- [2] Zhu C, Yan R, 2019, Influences of Tongmai Capsule Combined with Nicorandil on Coronary Blood Flow and Complications in Patients with Acute Myocardial Infarction After PCI. *Chinese Journal of Integrative Medicine on Cardio-/Cerebrovascular Disease*, 17(22): 13–16.
- [3] Martial H, Emmanuelle FC, 2019, Optimal Trial in Myocardial Infarction with the Angiotensin II Antagonist Losartan. The OPTIMMAL Trial: Losartan or Captopril After Acute Myocardial Infarction. *Lancet (London, England)*, 360(9348): 1886–1887.
- [4] Wang Z, Luo Z, 2019, A Case Report of Application of Indobufen in the Treatment of Acute Anterior Myocardial Infarction Complicated with Left Ventricular Mural Thrombosis. *Chinese Journal of Practical Internal Medicine*, 39(4): 92–94.
- [5] Pan J, Feng K, Chen L, et al., 2019, Takotsubo Syndrome Followed with Postoperative Colon Aneurysm: A Case Report. *Chinese Journal of Internal Medicine*, 58(4): 307–309.
- [6] Wang M, Li B, Wang S, et al., 2019, A Case of Acute Myocardial Infarction in a Young Female Patient After Heart Valve Replacement and Literature Review. *Hainan Medical Journal*, 30(12): 1616–1619.
- [7] Chen J, Li J, Wang Y, et al., 2019, A Case of Acute Myocardial Infarction Caused by Embolism in a Patient After Mechanical Aortic Valve Replacement. *Chinese Journal of Cardiology*, 47(1): 60–62.
- [8] Ederhy S, Cohen A, Bocarra F, et al., 2019, In-Hospital Outcomes and 5-Year Mortality Following an Acute Myocardial Infarction in Patients with a History of Cancer: Results from the French Registry on Acute ST-Elevation or Non-ST-Elevation Myocardial Infarction (FAST-MI) 2005 Cohort. *Archives of Cardiovascular Diseases*, 112(11): 657–669.
- [9] Han Y, Xu B, Xu K, et al., 2016, Six Versus 12 Months of Dual Antiplatelet Therapy After Implantation of Biodegradable Polymer Sirolimus-Eluting Stent: Randomized Substudy of the I-LOVE-IT 2 Trial. *Circulation: Cardiovascular Interventions*, 9(2): e003145.

- [10] Palmerini T, Benedetto U, Bacchi-Reggiani L, et al., 2015, Mortality in Patients Treated with Extended Duration Dual Antiplatelet Therapy After Drug-Eluting Stent Implantation: A Pairwise and Bayesian Network Meta-Analysis of Randomised Trials. *The Lancet*, 385(9985): 2371–2382.
- [11] Kuehneman T, Gregory M, de Waal D, et al., 2018, Academy of Nutrition and Dietetics Evidence-Based Practice Guideline for the Management of Heart Failure in Adults. *Journal of the Academy of Nutrition and Dietetics*, 118(12): 2331–2345.
- [12] Abdelrahman M, Subzposh FA, Beer D, et al., 2018, Clinical Outcomes of His Bundle Pacing Compared to Right Ventricular Pacing. *Journal of the American College of Cardiology*, 71(20): 2319–2330.
- [13] Walker MA, Tian R, 2018, Raising NAD in Heart Failure: Time to Translate?. *Circulation*, 137(21): 2274–2277.
- [14] Konstam MA, Kiernan MS, Bernstein D, et al., 2018, Evaluation and Management of Right-Sided Heart Failure: A Scientific Statement from the American Heart Association. *Circulation*, 137(20): e578–e622.
- [15] Lopes RD, Rordorf R, De Ferrari, et al., 2018, Digoxin and Mortality in Patients with Atrial Fibrillation. *Journal of the American College of Cardiology*, 71(10), 1063–1074.
- [16] Wang H, Chen Q, Li, Y et al., 2017, Prognostic Value of Galectin-3 on Admission in Chinese Patients with Heart Failure: A Prospective Observational Study. *Acta Cardiologica*, 72(2): 188–195.
- [17] Mancini GJ, Gosselin G, Chow B, et al., 2014, Canadian Cardiovascular Society Guidelines for the Diagnosis and Management of Stable Ischemic Heart Disease. *Canadian Journal of Cardiology*, 30(8): 837–849.
- [18] Hershberger RE, Siegfried JD, 2011, Update 2011: Clinical and Genetic Issues in Familial Dilated Cardiomyopathy. *Journal of the American College of Cardiology*, 57(16): 1641–1649.
- [19] Jolicœur EM, Dunning A, Castelvechio S, et al., 2015, Importance of Angina in Patients with Coronary Disease, Heart Failure, and Left Ventricular Systolic Dysfunction: Insights from STICH. *Journal of the American College of Cardiology*, 66(19): 2092–2100.

Publisher's note

Bio-Byword Scientific Publishing remains neutral with regard to jurisdictional claims in published maps and institutional affiliations.