

Comparison of Clinical Effect of PFNA and Internal Fixation with Anatomical Locking Plate of Proximal Femur in Treatment of Intertrochanteric Fracture of Femur

Lu Wanqing, Xiang Qingtian, Yu Yajun, Wang Chunhua, Wang Jiafei

Orthopaedics Department of Xiangshui County People's Hospital, Yancheng, Jiangsu, 224600

ARTICLE INFO

Article history:

Published online: 31st Mar, 2018

Corresponding author: Xiang Qingtian

Key words:

Intertrochanteric fracture of femur

Anatomical locking plate of proximal femur

Proximal Femoral Nail Antirotation

Internal fixation surgery

Therapeutic effect

ABSTRACT

Purpose: To investigate the clinical value of proximal femoral nail antirotation and anatomical locking plate of proximal femur in the treatment of intertrochanteric fracture of femur. **Methods:** The study group is treated with PFNA internal fixation. The control group is treated by internal fixation with anatomical locking plate of proximal femur. **Results:** The time of operation, the amount of intraoperative bleeding and the time of fracture healing in the study group are significantly less than those in the control group. The incidence rate of complication in the study group (3.23%) is significantly lower than that in the control group (17.2%). Data comparison shows $P < 0.05$. **Conclusion:** The curative effect and prognosis for patients with intertrochanteric fracture of femur treated by PFNA internal fixation are more ideal.

0 Introduction

Intertrochanteric fracture of femur is a common and frequently occurring orthopedics disease. At present, surgical internal fixation is mainly used to treat this disease, but it is still controversial how to select the internal fixator^[1]. This paper will select 186 patients with intertrochanteric fracture of femur in our hospital in January 2012 to February 2017 as the research object to explore the value of clinical treatment of Proximal Femoral Nail Antirotation (PFNA) and anatomical locking plate of proximal femur in the treatment of intertrochanteric fracture of femur, which can provide a reliable basis for improving patients' curative effect and prognosis. The details are as follows.

1 Data and method

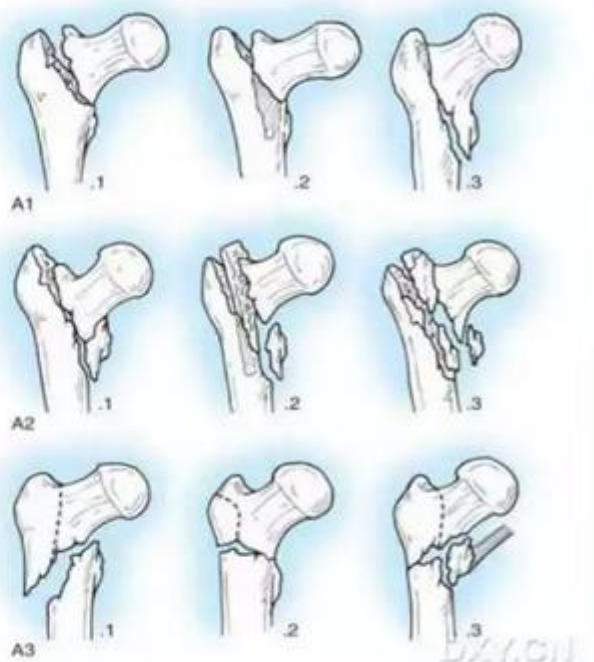
1.1 General information

Among 186 patients with intertrochanteric fracture of femur, there are 85 males and 101 females aged 57-89 years with an average of (73.14 ± 1.09) years. AO typing: 6 cases of type A1.1, 9 cases of type A1.2, 4 cases of type A1.3, 46 cases of A2.1 type, 49 cases of A2.2 type, 50 cases of A2.3, 9 cases of A3.1, 8 cases of A3.2 type, 5 A3.3 type. The selected 186 patients are divided into the study group ($n=93$) and the control group ($n=93$) by the random digital table method. The above related data of each group were compared $p > 0.05$ (comparability).

TYPING

■ AO typing

Some literature believe, compared with Evans-Jansen typing, it is easier to master and more accurate to differentiate stable and unstable fracture.



1.2 Methods

1.2.1 Operation methods

The study group is treated with PFNA internal fixation. Specific measures are as follows. After routine anesthesia, the surgical incision (3-5 cm in length) is performed at the femoral trochanter according to preoperative imaging findings (X-ray). The guide needle is placed in the posterior lateral of the apex of the trochanter of the femur and sent to the femoral intramedullary. The entrance of the trochanter is enlarged with a hollow drill, then the reaming treatment is performed along the direction of the guide needle and the proximal femoral nail antirotation is inserted into the medulla. After the above operation is completed, the needle is pulled out. Under the imaging monitoring (C arm X-ray machine), the longitudinal axis of femoral neck and proximal femoral nail antirotation are in parallel state. The length of the guide pin of the main nail is measured and the reaming is carried out (the lateral cortex of the femur). Confirm the right position and place the spiral blade. After locking it, the distal locking nail and the proximal end cap of the proximal femoral nail antirotation is placed in the appropriate position of the distal femur location hole under X-ray fluoroscopy. After the above operation is completed, the cavity is routinely flushed and sutured and bandaged (pressurized). The control group is treated by internal fixation with anatomical locking plate of proximal femur. Specific measures are as follows. After routine continuous epidural anesthesia, a surgical incision (length about 12-15cm) is performed on the lateral thigh trochanter to the

upper middle of the femur. After incision of skin, subcutaneous tissue and fascia lata, the lateral femoral muscle is effectively separated. After stripping the periosteum, the fracture end is exposed effectively, and the fracture end is reset and temporarily fixed. The anatomical locking plate of proximal femur is placed on the proximal lateral femur. After the above operation is completed, the femoral head and neck locking nail and the femoral shaft are locked and placed in turn. The whole process is in the C-arm X-ray machine perspective to complete the reset, fixed operation.

1.2.2 Observation indicators

①Operation situation: record the time of operation, the amount of intraoperative bleeding, the time of fracture healing and other indicators in two groups of patients with intertrochanteric fracture of femur; ②Prognosis: record two groups of complications.

1.3 Statistical methods

The related indexes of the two groups of operation obtained by the study are all measured data, which are indicated by $\bar{x} \pm s$. The correlation index of the two groups' prognosis is counted data, which is expressed by n (%). The data is passed into the SPSS.19 software and the corresponding inspection is carried out (t, X²). If $p < 0.05$, it is suggested that the correlation data difference exists statistically significance.

2 Result

2.1 Operation situation

The analysis shows that the time of operation, the

amount of intraoperative bleeding and the time of fracture healing in the study group are significantly less than those in the control group. Data comparison shows $P < 0.05$. As shown in table 1.

Table 1 Comparison of the related indexes between two groups of operation ($\bar{x} \pm s$)

Groups	Operation time (min)	Amount of intraoperative bleeding (ml)	Fracture healing time (weeks)
Study group (n=93)	55.69±9.53*	80.85±7.88*	10.15±1.17*
control group (n=93)	94.59±19.87	115.36±18.67	12.88±2.39

Note: * In contrast, $P < 0.05$ in the control group

2.2 Prognosis

The incidence rate of complication in the study group (3.23%) is significantly lower than that in the control

group (17.2%). Data comparison shows $P < 0.05$ (as shown in table 2). Note: there are no two or more complications occurring in the same patient at the same time in this study.

Table 2 Prognosis comparison of two groups [n (%)]

Groups	Abnormality of internal fixation material (loose, broken, screw cut out, etc.)	Coxa varus	Deep venous thrombosis of lower extremity	Pressure sore	Total
study group (n=93)	3 (3.23)	0 (0.00)	0 (0.00)	0 (0.00)	3 (3.23)
control group (n=93)	7 (7.53)	3 (3.23)	2 (2.15)	4 (4.30)	16 (17.20)

Note: * In contrast, $P < 0.05$ in the control group

3 Discussion

Anatomical locking plate of proximal femur is a common clinical internal fixation for intertrochanteric fracture of femur in the past, which can provide effective fixation of fracture end and solve the disadvantage of poor bending ability of common plate nails, so as to effectively restore the tension-resistant structure between femoral intertrochanteric. It has the characteristics of good holding power and low probability of screw loosening and so on [2]. However, studies have shown [3] that because the anatomical locking plate of proximal femur in the treatment process of femoral intertrochanteric will

cause greater trauma to the body, so it is not conducive to patients recover as soon as possible, and the incidence of complications is relatively high, which should cause the attention of the relevant medical staff.

Proximal Femoral Nail Antirotation is a new type of internal fixation for intertrochanteric fracture of femur in clinical practice in recent years. Because its design structure is more consistent with the local anatomy and biomechanics, it can provide better anti rotation and anti-cutting effect for the part, and the angle stability is ideal [4]. In addition, studies have shown [5] that the use of the Proximal Femoral Nail Antirotation only cause minor trauma to the body of patients with intertrochanteric fracture of femur, so it is beneficial to restore their

health as soon as possible after surgery. This study has also confirmed by group study that the time of operation, the amount of intraoperative bleeding and the time of fracture healing, and postoperative complication rate in the study group receiving PFNA internal fixation surgery are significantly less than those in the control group with anatomical locking plate of proximal femur. This conclusion is in accordance with the results of the study by Wang Kanshi et al.

In conclusion, the curative effect and prognosis for patients with intertrochanteric fracture of femur treated by PFNA internal fixation are more ideal, which is helpful to guarantee the quality of life. It is worth popularizing in the future.

References

- [1] He Zhenghua, Hu Awei, Xia Chunming, etc. The application of anatomical locking plate of proximal femur in the treatment of intertrochanteric fracture of femur in the elderly [J]. Chinese Journal of Bone and Joint Injury, 2010, 25(4): 316-317.
- [2] Guo Xiufeng, Wang Jianping, Yang Xinli, etc. Comparative analysis of the efficacy of PFNA internal fixation and locking plate in the treatment of intertrochanteric fracture of femur in the elderly [J]. China Practical Journal of Medicine, 2016, 43(22): 67-70.
- [3] Qian Mingquan, Zhu Guoxing, Chen Gang. Comparative study of dynamic hip screw combined with anti-spin barrier nail and proximal femoral nail in treatment of unstable femoral intertrochanteric fractures [J]. The Orthopedic Journal of China, 2013, 21(10): 957-962.
- [4] Wu Dou, Jin Dangyin, Liu Qiang, etc. A comparative study of local bone loss after DHS or PFNA in the treatment of femoral intertrochanteric fractures [J]. Chinese Bone and Joint Surgery, 2013, 26(S1): 61-65.
- [5] Wang Kanshi, Zhao Lei, Zhou Chao. Repair of senile stable femoral intertrochanteric fractures with locking proximal femoral plate [J]. Chinese Journal of Tissue Engineering Research, 2015, 19(26): 4208-4211.