

Photodynamic Therapy for Advanced Rectal Cancer: A Case Report

Lemei Chen¹, Yanping Liu¹, Ping Xie², Huizhen Fan^{2*}

¹School of Chemistry and Bioengineering, Yichun University, Yichun 336000, Jiangxi Province, China;

²Department of Gastroenterology, Yichun People's Hospital, Yichun 336000, Jiangxi Province, China

Abstract: Objective: To investigate the potential value of PDT(photodynamic therapy) in the treatment of rectal cancer by reviewing the diagnosis and treatment process of a patient with advanced rectal cancer who lost the opportunity of surgery.

Methods: Select the case data of a patient receiving photodynamic therapy in our hospital, and analyze the photodynamic mechanism, safety and efficiency, and discuss the efficacy of photodynamic therapy.

Results: After the patient received photodynamic therapy, re-examination of the endoscopy showed that the intestinal cavity was smoother than before, the bowel was difficult, and the symptoms of blood in the stool improved. **Conclusion:** Photodynamic therapy can be used as a radical or palliative treatment for clinical tumor treatment. Because of its advantages of minimally invasive, tissue-specific, repetitive and synergistic radiotherapy and chemotherapy, it plays an important role in early or middle-advanced colorectal cancer and is worthy of clinical promotion.

Keywords: Rectal cancer; Photodynamic therapy; Curative effect

Publication date: November, 2020

Publication online: 30 November, 2020

***Corresponding author:** Huizhen Fan, 18720928702@sina.cn

1 Introduction

According to epidemiological research, Colorectal cancer ranks third in incidence and second in mortality^[1]. In China, the incidence and mortality of colorectal cancer is still the fifth, and the data from 2000 to 2011 show that the incidence and

mortality of colorectal cancer are increasing year by year^[2]. Despite the continuous development of science and medicine, one-third of patients have metastases at the time of colorectal cancer diagnosis, and in every other patient, despite radical treatment, cancer recurrence still occurs^[3-4]. In recent years, with the exploration and development of laser medicine and other disciplines and fields, PDT has been widely used in the clinical treatment of rectal cancer. For early colorectal cancer patients, PDT can achieve clinical cure and is expected to preserve gastrointestinal function, while for patients in the middle and advanced stage, it can be effectively controlled and significantly improve the quality of life of patients. Relevant reports have confirmed that photodynamic therapy can be used as a radical or palliative treatment for patients with advanced rectal cancer^[5]. Moreover, it plays an important role in early or middle advanced colorectal cancer because of its advantages of minimally invasive, tissue-specific, repeatable and synergistic chemoradiotherapy.

2 Case summary

We report a 73-year-old man, he was admitted to our hospital for "dissolving mucus, bloody stools for 5 months, and having difficulty defecation for 1 month". 2019.5.6 Abdominal CT: The rectal wall is thickened in a circular shape, with rough edges, and multiple enlarged lymph nodes (T₄N₂M₀) (Figure 1). 2019.5.7 Ordinary colonoscopy: the mass is 3cm away from the anus and occupies the whole circumference of the tube wall, and the endoscopy cannot pass (Figure 2A). Use a rhino-gastroscope: 3-8cm from the anus to see the full picture of the mass. (Figure

2B). A treatment plan is drawn up. At 21:00 on May 8, 2019, 150 mg (hemoporphyrin injection) 150 mg (2.88 mg per kilogram of body weight) will be given intravenously. The first photodynamic therapy on May 11, 2019: Choose 4cm cylindrical optical fiber to irradiate three parts in three times, the transmission efficiency is 0.72, the output power is set to 2W, the irradiation time is 1200 seconds, and the irradiation energy for each point is 137.58 J/cm² (Figure 3). The second photodynamic therapy was performed on May 12, 2019. The endoscope was slightly smoother to clean up the necrotic tissue. Three parts were irradiated three times. The 4cm cylindrical fiber was used, the transmission efficiency was 0.72, the output power was 2W, and the irradiation time was set. For 1000 seconds, the irradiation energy at each point is 114.65 J/cm² (Figure 4). On the fourth day after treatment: A ring-shaped proliferative lesion can be seen at a distance of 3-8 cm from the anus under the endoscope, the surface is uneven, covered with dirty coating, the mucosa is obviously hyperemia, edema and superficial ulcers, and the endoscope passed smoothly (Figure 5). The patient was discharged after having difficulty defecation and improvement of bleeding symptoms. On June 18, 2019, after 1 month of photodynamic therapy, a re-examination of the endoscopy showed that a ring-shaped hyperplastic lesion was seen 3cm-8cm from the anus, the surface was uneven, covered with dirty moss, and the proximal mucosa was slightly congested and edema. The endoscopy passed smoothly. (Image 6).

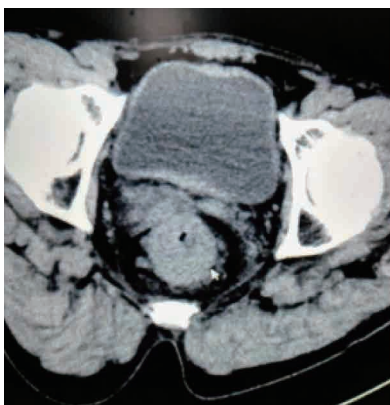

Figure 1. 2019.5.6 Abdominal CT: The rectal wall is thickened in a circular shape, with rough edges, and multiple enlarged lymph nodes nearby (T4N2M0)

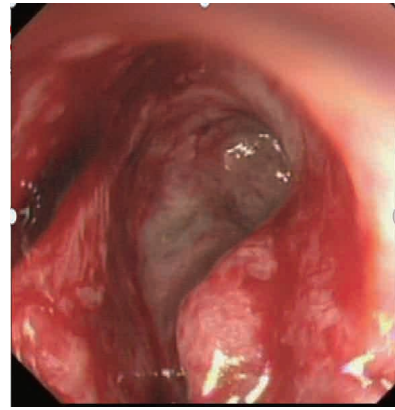


Figure2a. 12019.5.7 Ordinary colonoscopy: The tumor occupies the whole circumference of the tube wall 3cm from the anus, and the endoscope cannot pass

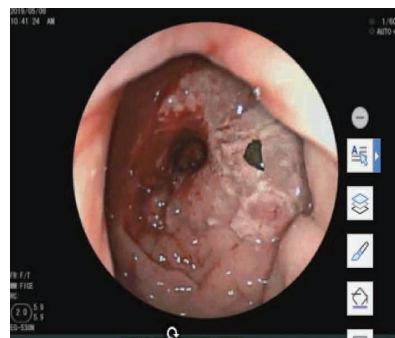


Figure2b. Naso-gastroscope: 3-8cm from the anus to see the full picture of the mass.

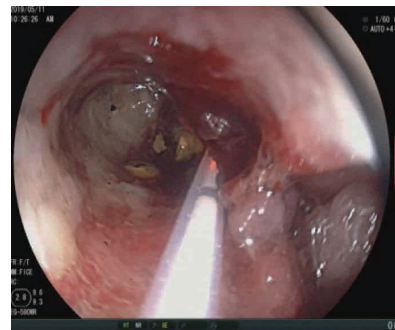


Figure 3. First photodynamic therapy endoscopic imaging on May 11, 2019

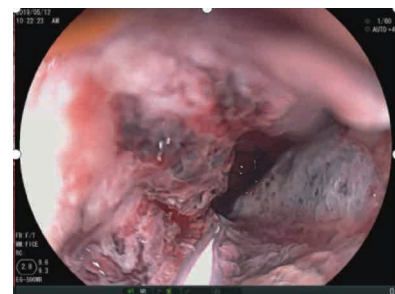


Figure 4. The second photodynamic therapy on May 12, 2019: the endoscope is smoother than before

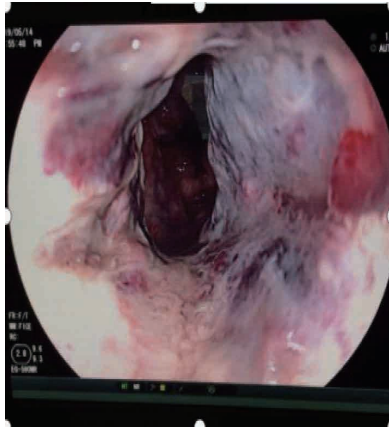


Figure 5. On the fourth day after treatment on May 14, 2019, endoscopy passed smoothly

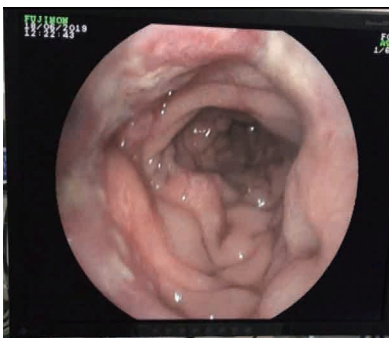

Figure 6. After 1 month of photodynamic therapy on June 18, 2019: 3cm-8cm from the anus, ring-shaped hyperplastic lesions are seen, the surface is uneven, covered with dirty moss, the proximal mucosa

3 Discussion

Colorectal cancer is a malignant tumor originating from the colorectal mucosa. It is one of the common gastrointestinal tumors. The clinical symptoms are mainly blood in the stool, changes in bowel habits, intestinal irritation and incomplete intestinal obstruction. Its morbidity and mortality are high. In addition, due to atypical early symptoms, poor patient awareness and low compliance, some areas lack standard early screening and diagnosis and treatment mechanisms. Most patients are already in the middle and late stages when they develop clinical symptoms. Timing of radical surgery. There are also some patients who relapse after surgery or radiotherapy and chemotherapy, and the intestinal obstruction cannot be resolved^[6]. The significant morbidity, high invasiveness, high recurrence rate and metastatic potential indicate that the most selective treatment for cancer cells is needed to increase the chance of cancer cells being destroyed without damaging normal and surrounding tumor cells, so as to minimize the occurrence of intestinal perforation and other

adverse events. However, the traditional treatment methods such as surgical resection, radiotherapy, chemotherapy, with large side effects and easy recurrence, obviously can not meet the clinical needs. In recent years, the treatment and prognosis of colorectal cancer patients have been improved through the development of new drugs and treatment schemes. However, tumor cells are increasingly resistant to chemotherapeutic and biological drugs for colorectal cancer, and these drugs have non-specific toxicity to healthy tissues.

PDT is a combined treatment with medicine and equipment, and it is a method that can achieve precise targeted treatment of tumors at the cellular level in a clinical sense. The basic process of PDT anti-tumor is mainly as follows: 1. When the endogenous or exogenous photosensitive material in biological tissue is illuminated by the corresponding wavelength, it absorbs the photon energy and changes from the ground state to the excited state. The photosensitive material in the excited state is very different. It is stable and quickly releases energy after physical de-excitation or chemical de-excitation process and returns to the ground state. The physical de-excitation process can produce fluorescence, and the diagnosis of diseases can be carried out by analyzing the fluorescence spectrum. 2. The chemical de-stimulation process can generate a large amount of reactive oxygen species, the most important of which is singlet oxygen. Reactive oxygen species can interact with a variety of biological macromolecules to produce cytotoxicity, damage cell structure or affect cell function, and kill tumor cells at the same time. Destroying tumor blood vessels, causing tumor necrosis and shedding, thus producing therapeutic effect^[7].

It not only has an anti-tumor effect on tumor cells, but also has an anti-tumor effect on tumor cells. Early inflammatory reaction after PDT leads to tumor ischemia and ischemia-reperfusion injury, which plays an important role in tumor elimination and long-term control. Oxidative stress produced by PDT triggers a series of protective signal transduction pathways, including the expression of transcription factors such as NF- κ B, AP-1 and heat shock protein, which produces a large number of cytokines, adhesion molecules, costimulatory molecules and important immune related mediators, which accelerates and enhances the inflammatory

response^[7-8], and skillfully utilizes the anti-tumor immune effect of PDT, Improve the curative effect and reduce the adverse reactions. In addition, PDT is a local treatment for colorectal cancer, which can release thromboxane from vascular endothelial cells and neutrophils at the irradiated site, causing vasoconstriction and thrombosis, thus forming anti-tumor effect. PDT can also induce apoptosis of cancer cells, cause local microvascular damage, increase immune function, significantly increase lymphocyte transformation rate of thymus and spleen, enhance natural killer cell activity, and increase the ratio of CD4⁺/CD8⁺, so as to resist tumor^[9].

Compared with traditional surgery, chemotherapy and radiotherapy, photodynamic therapy has many inherent advantages: it can accurately locate tumor tissue, is a non-invasive treatment, can be repeated for multiple operations, is convenient and has small adverse reactions, and is selective Good, wide application range, and can protect important organ functions. Moreover, photodynamic therapy will not cause scarring stenosis in the entire process of treating colorectal cancer. Because collagen is not destroyed, it will not reduce the mechanical tension of the rectum. It has an immediate effect on improving obstruction, which can be significant in the short term. Improve the quality of life of cancer patients and prolong the survival period of patients. Studies have found that photodynamic therapy has an effective rate of up to 70% in controlling bleeding, relieving pain and alleviating intestinal obstruction in patients with advanced colorectal cancer^[10-12].

This patient is an effective case of photodynamic therapy for advanced colorectal cancer. After receiving photodynamic therapy, the tumor tissue necrosis in the intestinal cavity was clearly visible under endoscopy, and the lumen was unobstructed. The symptoms of hematochezia, dysuria and incomplete intestinal obstruction were improved after discharge. One month after the patient's photodynamic operation, a reexamination of the endoscopy showed that a ring-shaped hyperplastic lesion was seen 3cm-8cm from the anus, the surface was uneven, covered with dirty moss, and the proximal mucosa was slightly congested and edema. The endoscopy passed smoothly, and the symptoms were partially relieved. Treatment effective. The patient's tumor penetrates the viscera of the peritoneum and has regional lymph node

metastasis. In the later stage, a second photodynamic therapy combined with low-dose chemotherapy can consolidate the curative effect and reduce the probability of local recurrence or distant metastasis.

Although PDT therapy is more and more widely used in colorectal cancer, it has its own limitations, such as the depth of tumor tissue killing. The presence of blood clots in the tumor tissue, necrotic tissue and the photosensitizer itself absorbs a certain amount of light and other factors will affect the penetration depth of the laser in the tissue; incomplete laser irradiation, leaving the lesion, is likely to cause local tumor recurrence and remote metastasis; PDT The phototoxic effect of the therapy; intestinal stenosis; hemorrhage; the formation of intestinal fistula due to excessive treatment^[8].

In recent years, PDT has been used in the treatment of colorectal cancer. After PDT treatment, the tumor necrosis can be as deep as 5mm. During the follow-up period of 15 months, the complete remission rate was 50%. In a group of 10 cases of PDT treatment, 7 cases of bleeding, constipation and other symptoms were well controlled^[13]. The larger the mass of colorectal cancer, the more complications after PDT treatment, the worse the curative effect. Therefore, it is suggested to improve the screening mechanism of early cancer and apply PDT to colorectal cancer patients with early lesions and small lesions^[8].

PDT therapy can play a role in different stages of tumors. For patients with early tumors, it can cure the disease and preserve the function; for advanced patients, it can effectively control tumor growth and improve the quality of life of patients; for advanced patients, it can improve symptoms. Extend life. Domestic research on the quality of life of diseases has been ignored for a long time. Although this aspect has been gradually strengthened in recent years, the research on photodynamic therapy to improve the quality of life of patients with gastrointestinal tumors is far from enough. PDT has not yet been used as a radical replacement therapy for early CRC, but it is undoubtedly a great hope for patients who, like this patient, missed the opportunity of surgery and actively sought minimally invasive palliative interventional treatments, because These treatments can not only prolong the life of the patient, but also improve the comfort of the patient and improve the clinical symptoms. A targeted study on the quality of life of patients has shown that it can improve

the quality of life of patients in the physical and psychological fields, especially the recent quality of life. Therefore, the change process of their subjective perception can be judged from the changes in the quality of life. Reflect the changes of the condition from the perspective of subjective perception, which helps clinicians to comprehensively measure the condition and judge the effect^[8].

In the clinical diagnosis and treatment of colorectal cancer, we must first use modern medical methods, pay attention to early tumor screening, and use surgical resection or early application of PDT as a radical treatment method as much as possible; secondly, for patients with advanced stages, PDT therapy can be used as adjuvant treatment means, synergistic effect with radiotherapy and chemotherapy, and jointly exert anti-tumor effect. At the same time, care should be taken in the settings of photosensitizer selection, light dose, and light parameters. There is a connection between each segment during irradiation, and it must exceed the edge of the lesion by at least 0.5 cm so that the light range can fully cover the lesion and monitor the patient's vital signs to prevent the occurrence of adverse events. For the treatment of colorectal patients in the middle and late stages, the focus should be on improving the clinical symptoms, improving the quality of life, alleviating the suffering of patients, and giving as much human care as possible. The 5-year survival rate of colorectal cancer has been hovering between 50% and 60%. One of the reasons is the recurrence of colorectal cancer after surgery. This requires clinicians to visit regularly to understand the clinical symptoms and tumor indicators before and after treatment. , Endoscopic performance improvement; changes in quality of life indicators; complications and side effects. Improve patient compliance, timely follow-up diagnosis, and prolong life cycle.

In summary, photodynamic therapy is another major and substantial breakthrough in the treatment of colorectal cancer after surgery, radiotherapy, chemotherapy, and immunotherapy. It is worthy of clinical promotion.

References

- [1] Bray F. Global cancer statistics 2018: GLOBOCAN estimates of incidence and mortality worldwide for 36 cancers in 185 countries[J]. *CA Cancer J Clin*, 2018. 68(6): 394-424.
- [2] Chen W. Cancer statistics in China, 2015[J]. *CA Cancer J Clin*, 2016. 66(2): 115-32.
- [3] Siegel RL. Colorectal cancer statistics, 2020. *CA Cancer J Clin*, 2020. 70(3): 145-164.
- [4] Siegel RC. Desantis and A. Jemal, Colorectal cancer statistics, 2014. *CA Cancer J Clin*, 2014, 64(2): 104-117.
- [5] Barr H. Photodynamic therapy for colorectal cancer: a quantitative pilot study. *Br J Surg*, 1990, 77(1): 93-96.
- [6] Ferlay J. Cancer incidence and mortality patterns in Europe: estimates for 40 countries in 2012[J]. *Eur J Cancer*, 2013, 49(6): 1374-1403.
- [7] Joy B. Embelin (2,5-dihydroxy-3-undecyl-p-benzoquinone): A bioactive molecule isolated from *Embelia ribes* as an effective photodynamic therapeutic candidate against tumor in vivo[J]. *Phytomedicine*, 2014, 21(11): 1292-1297.
- [8] Lu LQ. Observation of the short-term curative effect of Photofrin in the treatment of advanced colorectal cancer[J]. *Guangdong Medicine*, 2010, 31(6): 737-739.
- [9] Han R. Experimental study on the effect of hematoporphyrin photodynamics on the metastatic potential of human cholangiocarcinoma cells[J]. *Chinese Journal of Cancer Prevention and Treatment*, 2014, 21(2): 113-117.
- [10] Miao XY. Application of photodynamic therapy in palliative treatment of patients with various malignant tumors[J]. *Journal of Laser Biology*, 2013, 22(2): 114-118.
- [11] Huang SF. Effect of photodynamic antibacterial chemotherapy on wound flora and wound healing of patients with deep infections after finger bites[J]. *Chinese Journal of Physical Medicine and Rehabilitation*, 2015, 37(2): 146-148.
- [12] Wang PR. Plum-blossom needle tapping enhanced aminolevulinic acid photodynamic therapy for photo-induced keratosis, basal cell carcinoma, and squamous cell carcinoma[J]. *Chinese Journal of Dermatology*, 2015. 48(02): 80-84.
- [13] Bei CH. The effect of photodynamic therapy combined with chemotherapy on the efficacy and quality of life of elderly digestive tract tumors[J]. *Chinese Journal of Clinical Rehabilitation*, 2004(26): 5518-5520.