

Value of V-Y Advancement Flaps in the Coverage of Cutaneous Loss of Substance

HA Hissein*, JL Mokako, A Meftah, M Benkhaldoun, S Sabur, A El Harti, A Chakir, M Diouiri

National Centre for Burns, Plastic and Reconstructive Surgery, CHU Ibn Rochd, Casablanca/Morocco

*Corresponding author: HA Hissein, hissene1@gmail.com

Copyright: © 2023 Author(s). This is an open-access article distributed under the terms of the Creative Commons Attribution License (CC BY 4.0), permitting distribution and reproduction in any medium, provided the original work is cited.

Abstract: *Objective:* We aimed to provide an update and highlight the value of V-Y advancement flaps in the management of cutaneous loss of substance (LOS). *Methods:* We included 18 patients in whom cutaneous reconstruction was performed at various sites between 2019 and 2021. Skin coverage was provided by means of unilateral or bilateral VY advancement flap. Among the 18 patients, 13 were men and 5 were women. The age of the patients ranged from 8 to 75, with an average age of 46.8. Perineal scrotal reconstruction was performed in 5 cases, sacral in 5 cases, plantar in 3 cases, ischial in 1 case, lumbogluteal in 2 cases, retroauricular in 1 case, and forearm in 1 case; 7 cases had bilateral V-Y advancement flap, while 11 cases had unilateral flap. We studied the indications, the size of the defect (4 cm × 5 cm to 20 cm × 30 cm), postoperative complications, and patient satisfaction. *Results:* No flap defatting was necessary. Long-term results in terms of scarring, functionality, and cosmetic appearance of the reconstructed area were considered satisfactory by the patients. *Conclusion:* Coverage of cutaneous LOS is a daily procedure for plastic surgeons. Since the V-Y advancement flap is a simple, useful, and reliable coverage technique with low morbidity, it should be an option in cutaneous reconstruction.

Keywords: Horizontal V-Y advancement flap; Tissue defect; Perineal scrotal; Ischial; Sacral tissue defect

Online publication: June 7, 2023

1. Introduction

The coverage of skin breakdowns is a major concern among plastic surgeons. Direct closure, skin grafts, dermal substitutes, or directed wound healing are simple and effective methods for specific indications [1-3]. When it comes to the use of flaps, plastic surgeons are faced with a variety of choices. Therefore, we aimed to review and highlight the value of V-Y advancement flaps in the management of cutaneous loss of substance (LOS) in this paper.

V-Y flap was first described by Dieffenbach in 1845. Its name corresponds to the appearance of the skin patterns before and after mobilization. It exists in two forms, bipedicle and island. In the latter case, the coverage of cutaneous LOS is ensured by the sliding of a triangular isosceles flap whose base is adjacent to the LOS. The area of LOS is covered by the displacement of the flap is divided on either side of the triangle into two parallelograms whose height increases with the angle of the apex of the triangular flap and the displacement of the flap (**Figure 1**). The angle of the apex is typically between 20° and 40° [4,5], and the suture tension is maximum at the apex of the flap.

The possibilities of flap displacement are related to the nature of the support. Classically, the flap rests on its vascular support (subcutaneous tissue, muscle, and perforator) [6]. The possibilities of displacement are linked to the elongation capacities of this support, which allows translation with the possibility of rotation.

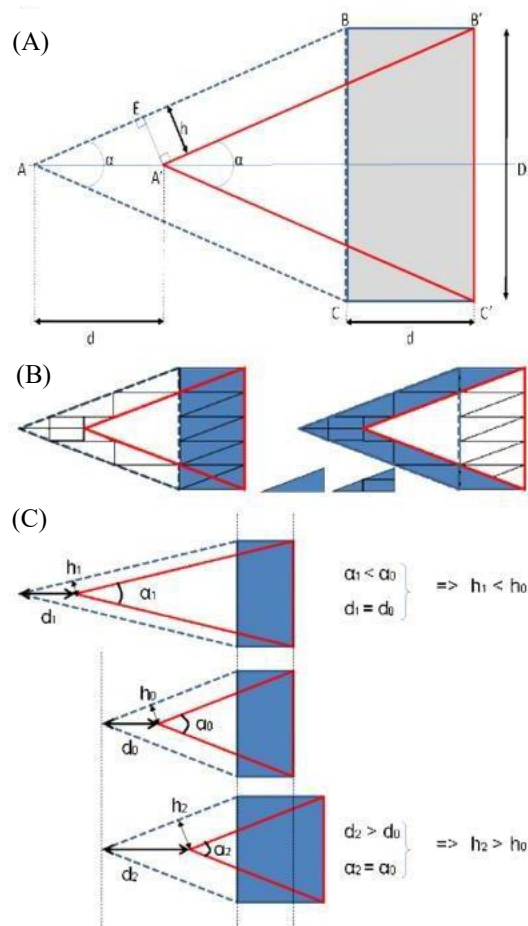


Figure 1. (A–B) The ABC flap moves a distance d and becomes $A'B'C'$, covering the rectangular defect $BB'C'C$. The area of the LOS covered by the displacement of the flap is divided on either side of the triangle into two parallelograms: $AA'B'B$ and $AA'C'C$ of height h . (C) Using trigonometry, it is easy to demonstrate that $h = d \cdot \sin(\alpha/2)$. Since h corresponds to the distance between the two edges before suturing, it is clear that h increases with the angle of the flap α and displacement d . (D) In case of low skin elasticity, angle α must be small, and the flap, longer. The skin tension is maximum at A' , as the distance between the two edges is $2h$, and the skin tension increases with d [5].

In our study, we evaluated the cosmetic appearance and functionality of 18 patients who benefited from cutaneous reconstruction using this type of flap.

2. Methods

2.1. Participants

We included 18 patients who were operated between 2019 and 2021 at the National Centre for Burns, Plastic and Reconstructive Surgery, Ibn Rcohd University Hospital, Casablanca/Morocco. These patients were referred to us from various departments, including visceral surgery, pediatrics, dermatology, and urology, for the management of one or more substance losses to either Fournier's gangrene, pressure ulcers, abscesses, or extravasations. There was a case involving the sacral region after excision of a sarcoma performed by our department. Skin coverage was provided by means of unilateral or bilateral V-Y advancement flap. Among the 18 patients, 13 were male and 5 were female. The age of the patients ranged from 8 to 75, with an average age of 46.8. Cutaneous LOS involving the perineal scrotal region were observed in 5 cases, sacral in 5 cases, plantar in 3 cases, ischial in 1 case, lumbo-gluteal in 2 cases, retroauricular in 1 case, and forearm in 1 case; 7 cases had bilateral V-Y advancement flap, while 11 cases had unilateral flap (Table 1).

Table 1. 18 cases of V-Y advancement flaps

Case	Age	Gender	History	Indication	LOS size (cm)	Type of V-Y flap	Complications
1	75	M	Chronic smoking	Post-Fournier's gangrene	7 × 10	Double V-Y flap + partial-thickness skin graft on the penis sheath	
2	56	M	Type 2 diabetes and overweight	Anal abscess	12 × 14	Double V-Y flap	
3	60	M		Sacral bedsore	10 × 12	Double V-Y flap	
4	70	M	Chronic smoking	Post-Fournier's gangrene	8 × 14	Double V-Y flap	
5	25	M		Post-Fournier's gangrene	12 × 15	Double V-Y flap + burial of the gonads in the remaining scrotal pouch	Partial necrosis
6	35	F	Paraparesis	Ischial sore	15 × 20	Unilateral V-Y flap	
7	65	M	Type 2 diabetes	Sacral bedsore	13 × 15	Double V-Y flap	
8	25	F		Pilonidal cyst	7 × 12	Unilateral V-Y flap	
9	35	M		Post-plantar hemangioma	5 × 5	Unilateral V-Y flap	
10	65	M		Sacral bedsore (hospitalized in ICU for respiratory infection)	12 × 15	Unilateral V-Y flap	
11	25	M		Heel spur	5 × 6	Unilateral V-Y flap	
12	35	M		Forearm potassium extravasation	5 × 5	Unilateral V-Y flap	
13	70	M		Retroauricular post-traumatic accident	4 × 5	Unilateral V-Y flap	
14	65	M	Type II diabetes	Plantar puncture wound	5 × 5	Unilateral V-Y flap	
15	35	F		Post-gluteal injection with Fenugreek oil	10 × 14	Unilateral V-Y flap	
16	42	M	Chronic smoking	Post-Fournier's gangrene	6 × 15	Unilateral V-Y flap	
17	38	F		Post-intramuscular injection abscess	20 × 30	Unilateral V-Y flap	
18	28	F		Post-tumor resection	10 × 10	Double V-Y flap	

Abbreviations: F, female; ICU, intensive care unit; LOS, loss of substance; M, male.

We studied the indications, size of defect (4 cm × 5 cm to 20 cm × 30 cm), postoperative complications, and patient satisfaction.

After initial management by the aforementioned departments, for some, in the intensive care unit (ICU), and control of general, local, and biological infectious states, the patients were referred to us for cutaneous reconstruction.

All the patients followed-up in our department. After complete healing, patients with colostomy were referred to the visceral surgery department for continuity of care.

2.2. Surgical technique

Since the V-Y advancement flap rests on its vascular support (subcutaneous tissue, muscle, and perforator), the possibility of displacement is linked to the elongation capacity of this support, which allows for translation ^[6]. The procedure, as shown in **Figures 2–8**, was performed under general or spinal anesthesia, rarely under local, except in cases of small localized lesions. It began with the preparation of the area to be covered: the recipient area (**Figures 2 and 6**). Once this area was prepared, one or two isosceles triangles (depending on whether the flap was raised unilaterally or bilaterally) were drawn, with the lateral edges of the LOS as the base. A flap marker was made before surgery and readjusted intraoperatively according to the size of the defect (**Figure 6**). It may encompass one or more perforators or be randomly selected. The apex of the flap was marked, with its base located on the edges of the LOS. The underlying fascial or fascial plane was dissected, and the flap was advanced in a V-Y direction. The suture began at the distal end of the flap, preventing the flap from receding. The elasticity and plasticity of this type of flap allowed for perfect shaping and adaptation to the defect. The donor site and the flap were sutured in two planes: deep interrupted inverted stitches with absorbable sutures and superficial skin with non-absorbable sutures. Suction drainage or a Delbet blade was used depending on the presence of persistent dead space during flap positioning (**Figures 4 and 8**).

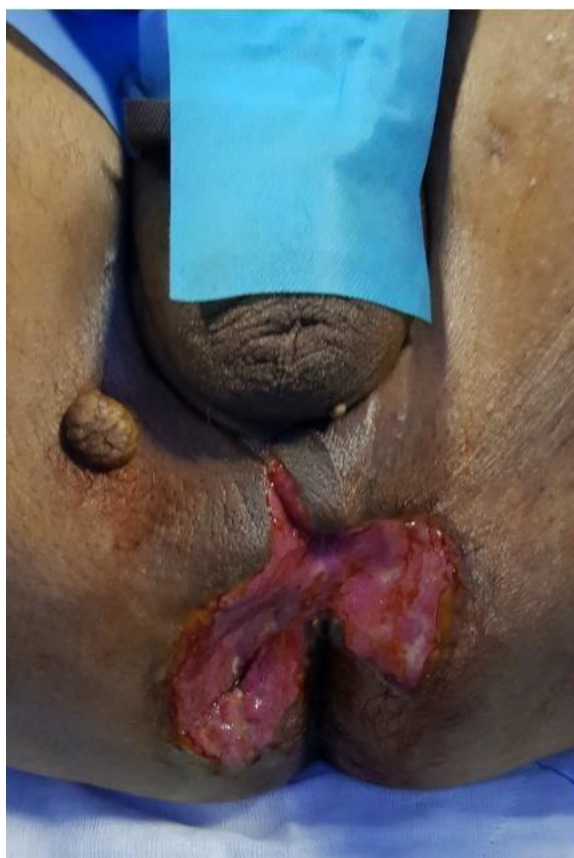

Figure 2. Post-gangrene LOS of the posterior perineum

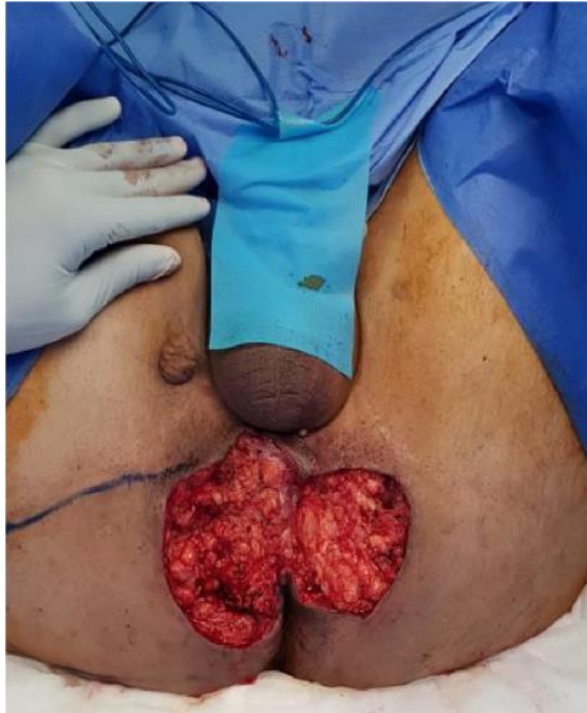

Figure 3. Removal of the sclerotic margin and drawing of a double V-Y advancement flap

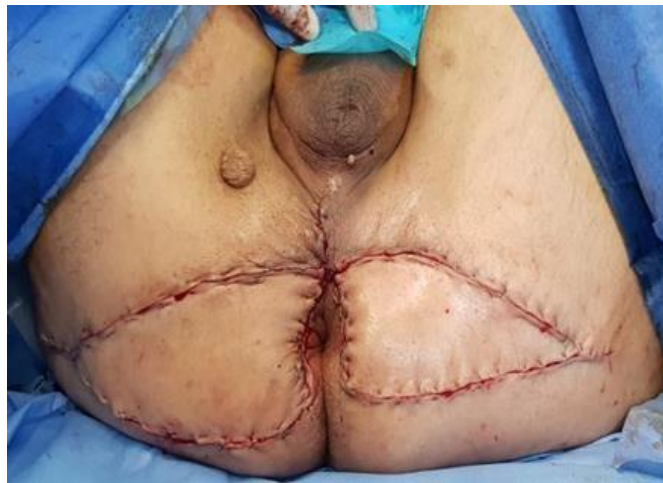

Figure 4. Covering the defect with a double V-Y advancement flap

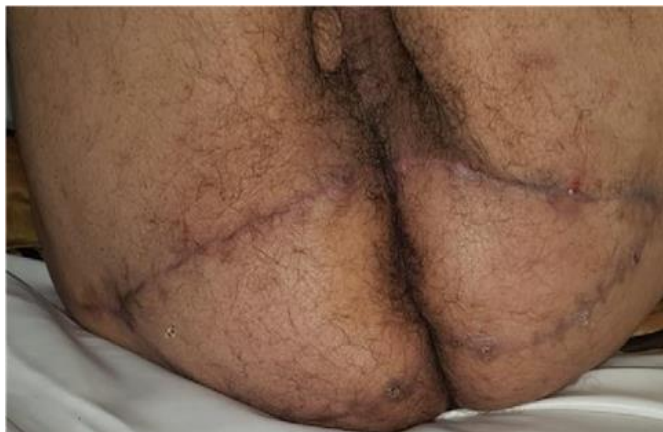

Figure 5. Outcome at 9 months

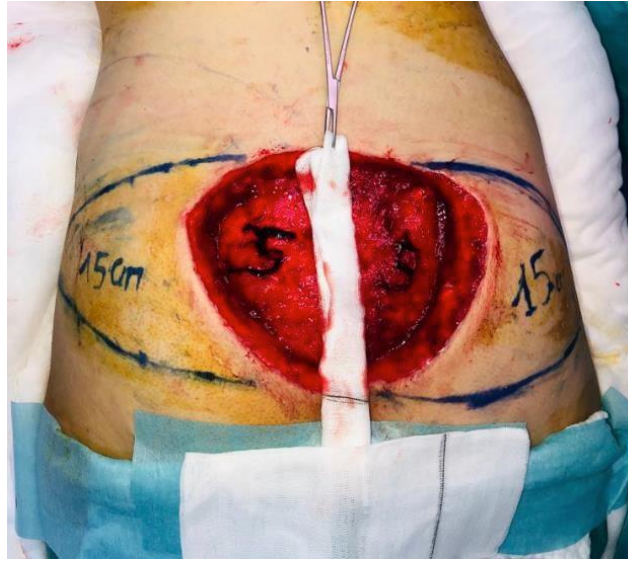

Figure 6. 10 cm × 10 cm sacral LOS

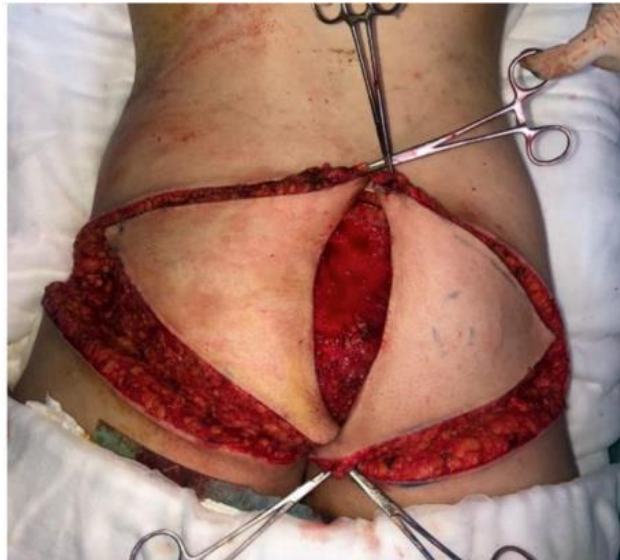

Figure 7. Translations of two V-Y flaps after excision of Ewing's sarcoma on the sacral LOS

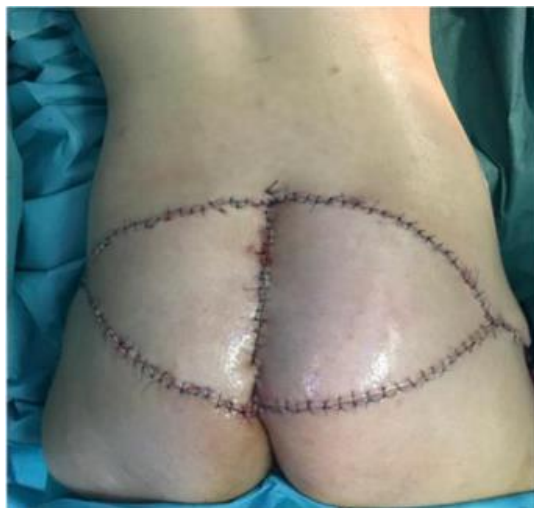

Figure 8. Immediate outcome

Postoperatively, the patients were monitored regularly until the application of the first postoperative dressing on day 3, followed by the removal of the drain or the Delbet blade depending on case. Systemic antibiotic therapy based on amoxicillin-clavulanic acid or adapted according to the isolated microorganism (one case in our study) was initiated, along with low molecular weight heparin (LMWH) at an iso-coagulant dose based on the prophylactic anticoagulation protocol, except in children.

2.3. Patient follow-up

The patients were seen in consultation after discharge from the hospital for follow-up of scar care.

3. Results

3.1. Complications

Out of the 18 patients, we had one case of partial flap necrosis. The patient was a 25-year-old boy with post-Fournier's gangrene perineal scrotal LOS who developed local infection on postoperative day 6. The local samples allowed for readjustment of antibiotic therapy, and the partial necrosis progressed well to complete healing within 22 days, without retractive sequelae.

3.2. Patient satisfaction

A survey was carried out when the patients were reviewed. Simple verbal questions were posed. In terms of donor and recipient sites, the patients were not bothered by their scars, which were concealed, painless, and pliable. The patients were satisfied with their scars, as evidenced by five clinical cases.

3.2.1. Case 4: Reconstruction of posterior perineal LOS post-Fournier's gangrene with double V-Y flap

A, a 70-year-old man and a chronic smoker of 10-pack-years, presented with Fournier's gangrene and was initially managed by the urology department. He had undergone debridement with colostomy. The patient was subsequently referred to us for management of an 8 cm × 14 cm LOS (**Table 1**). The LOS was covered by a double V-Y advancement flap (**Figures 2–5**).

3.2.2. Case 10: Reconstruction of sacral LOS with unilateral V-Y flap

Following ICU admission for respiratory disease, the patient, a 70-year-old man, presented with a 12 cm × 15 cm Grade III sacral sore. The patient was intubated during his stay in the ICU. On discharge, he was referred to us for management of the pressure ulcer. The sacral LOS was covered by a large left unilateral V-Y advancement flap (**Figure 9**).

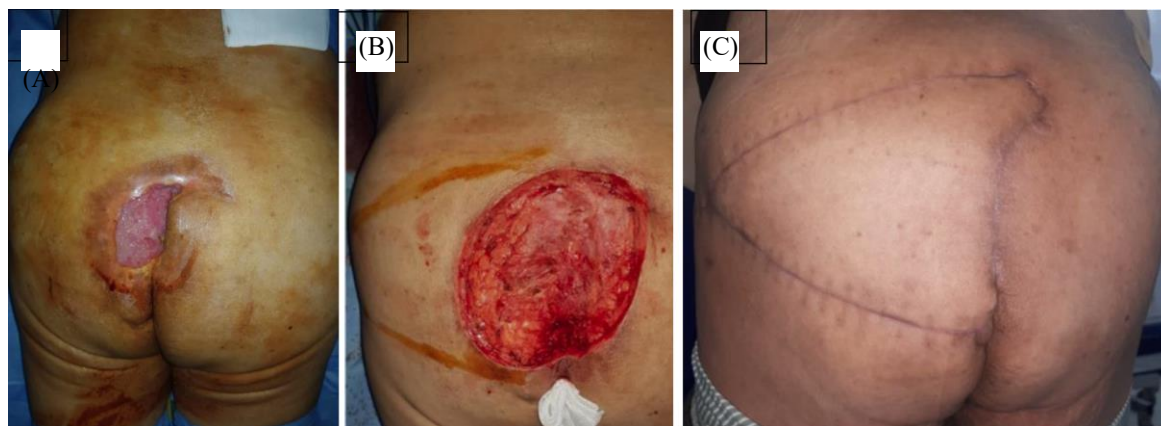


Figure 9. Reconstruction of sacral LOS with unilateral V-Y flap. (A) Pressure ulcer. (B) Debridement and flap placement. (C) Outcome at 6 months.

3.2.3. Case 16: Reconstruction of perineal LOS with unilateral V-Y flap

Y, a 42-year-old chronic smoker, presented with a cutaneous LOS of about 6 cm × 15 cm in size at the perineal region post-Fournier's gangrene. The patient was referred to us by the visceral surgery department. He underwent initial debridement with colostomy. Reconstruction of this LOS was performed with unilateral V-Y advancement flap (**Figure 10**).

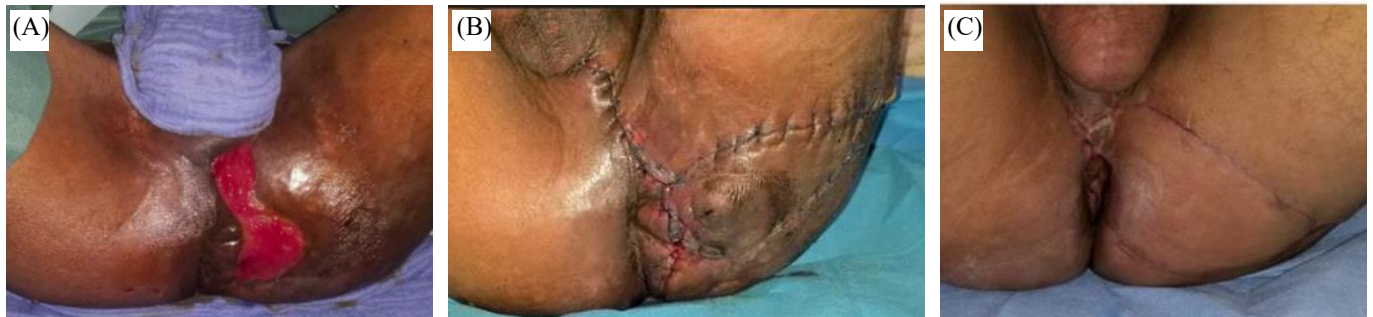

Figure 10. Reconstruction of perineal LOS with unilateral V-Y flap. (A) Perineal LOS. (B) Coverage with a V-Y flap. (C) Outcome at 9 months.

3.2.4. Case 17: Reconstruction of lumbo-gluteal LOS with unilateral V-Y flap

K, a 38-year-old overweight lady, presented with a cutaneous lumbo-gluteal LOS of about 20 cm × 30 cm after intramuscular injection. The patient was referred to us by the visceral surgery department. She initially presented with necrotizing fasciitis at the injection site, which had spread to the left lumbo-gluteal region. She underwent debridement with broad-spectrum antibiotics under the visceral surgery department. Reconstruction of this LOS was performed with unilateral V-Y advancement flap (**Figure 11**).

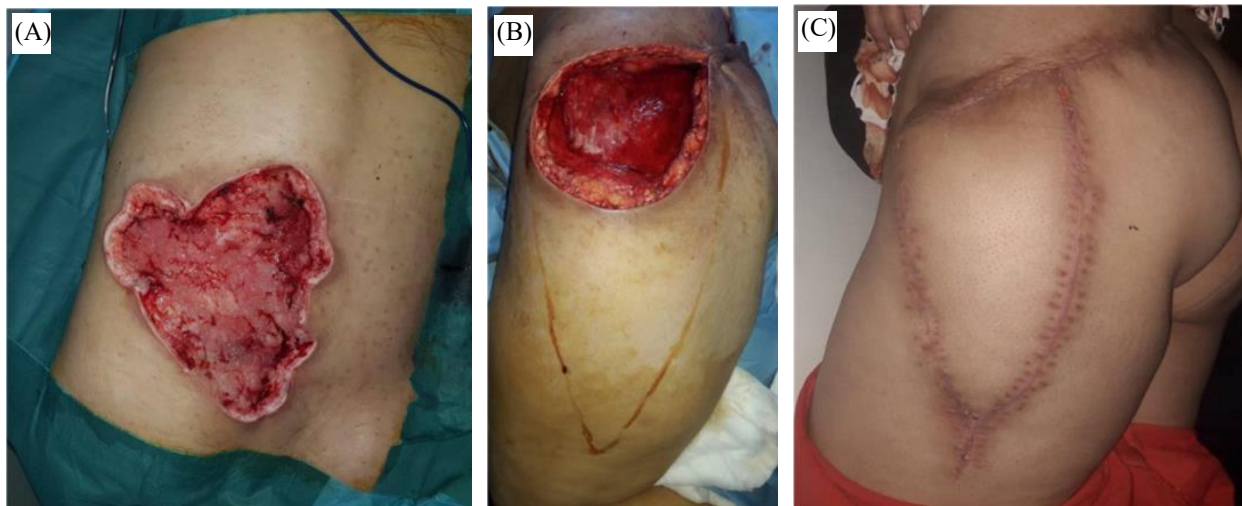


Figure 11. Reconstruction of lumbo-gluteal LOS with unilateral V-Y advancement flap. (A) Lumbo-gluteal LOS after debridement. (B) Course of a large V-Y advancement flap. (C) Outcome at 3 months.

3.2.5. Case 18: Reconstruction of sacral LOS after excision of Ewing's sarcoma with bilateral V-Y flap

K, a 28-year-old lady, with no previous history, presented with a sacral cutaneous LOS of approximately 10 cm × 10 cm following excision of Ewing's sarcoma. The patient was referred to us by the dermatology department. After histological confirmation of the malignant nature of the excision with healthy margins, the reconstruction of the LOS was ensured by means of bilateral V-Y advancement flap (**Figures 6–8**).

4. Discussion

The use of V-Y advancement flaps in the coverage of cutaneous LOS at various locations was demonstrated in this study. There are several options for cutaneous reconstruction, including directed wound healing, skin grafting, fascia or fat flap, and musculocutaneous flap [7-10].

Directed wound healing, which consists of alternating pro- and anti-inflammatory dressings to direct the different phases of wound healing (particularly the budding phase), can be used either as a temporary solution (in preparation for skin grafting for example) or a definitive solution. Its disadvantages include the rather long delays, as it often concerns fragile and/or diabetic areas, the need to use dressings from different families, which can be expensive, depending on the state of the wound, and the pain experienced by the patients when changing dressings in some sensitive areas. The risk of retraction compromises the aesthetic and functional outcomes. Therefore, it should be reserved for cases where other means are not indicated or are unsuitable [12,13,20].

Directed wound healing can be assisted by vacuum-assisted closure (VAC) or negative pressure wound healing, which allows effective detersion and stimulates the formation of granulation tissue [13]. However, it may be quite unpleasant to place a VAC system at the perineal scrotal area and challenging to achieve a complete seal, making leakage quite common and its use uncertain, not to mention the exorbitant price associated with this procedure.

There are great difficulties in the use of simple skin grafts, including the risk of disunions, close to that of direct closures, due to the lack of subcutaneous tissue, the contrariety in protecting the graft postoperatively, and the high local septic risk due to the proximity of the anogenital sphere. In other areas, skin grafts require a period of budding to prepare the subsoil for the grafts, which would take up additional time, on top of its disadvantages (frequency of maceration and difficulties in removal, especially on fragile ground and in a humid area) [10,20].

Direct closure is not feasible with the size of the losses in the aforementioned cases.

Other local flaps such as rotation flap, Limberg flap, medial thigh flap, and keystone flap are also easy to use, but because of the size and location of the LOS in our cases [14-17], we thought it wise to reserve them for other cases.

The V-Y flap is an advancement flap that involves two planes of movement (horizontal and vertical) with a pivot point in the vertical plane (**Figure 12**). This pivot point is explained by the projection of the triangular base, which is advanced into the tissue and behaves more like a pivot plane than a pivot point. Understood in this way, it is the level of the flap that remains attached to the body; in other words, it is the pedicle that allows the movement.

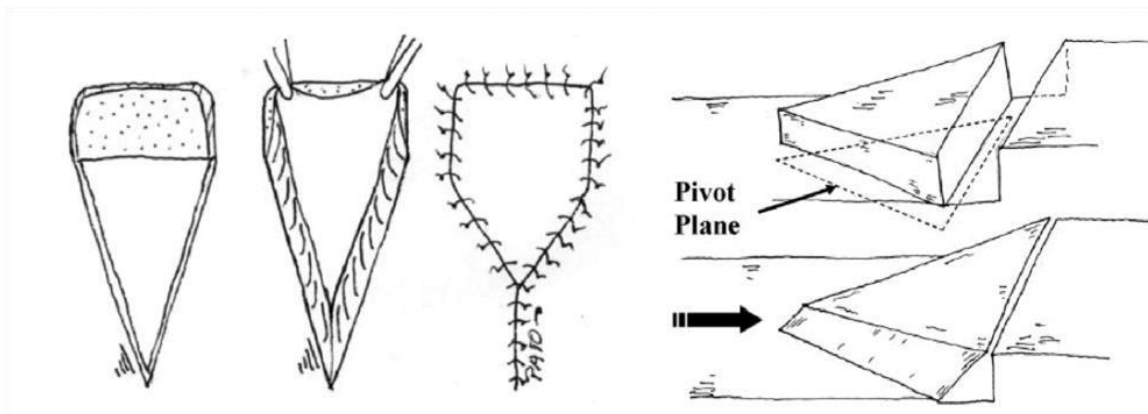


Figure 12. (Left) Horizontal plane analysis. (Right) Vertical plane analysis showing the triangular base of the flap where the pivotal plane of movement is located. This plane is the pedicle of the flap [4].

When the flap is designed using the method explained above, an isosceles triangle is obtained in the horizontal plane. Once the height (h) of this triangle is determined, the angle (α) is divided, and a new, smaller triangle is formed (**Figure 13**).

$$\tan \alpha/2 = (LD/2)/h$$

Then, the height (h) of the triangle and the length of the V-Y flap are recalculated as follows:

$$h = (LD/2)/\tan \alpha / 2$$

The angle (α) is very important. In order to determine the angle, the location of the LOS, the elasticity of the surrounding tissue, and the cause of the injury (subjective qualitative parameters) must be taken into account [4].

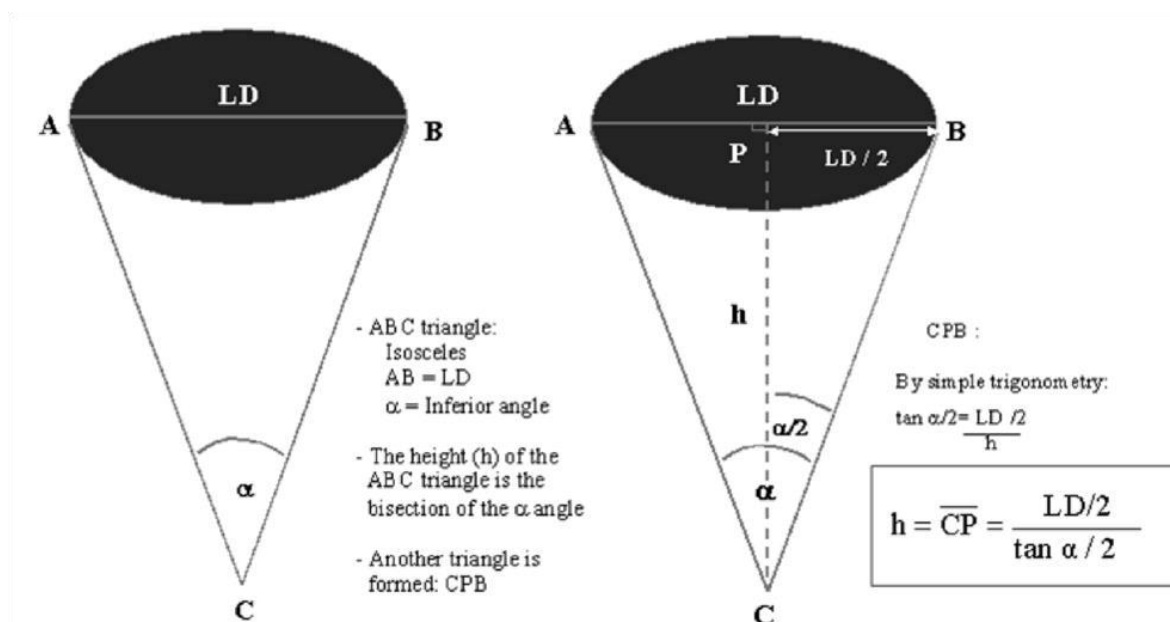


Figure 13. (Left) Design of the isosceles triangle in horizontal plane analysis. (Right) By fixing the height of this triangle, a new triangle, CPB, is formed. The height is the bisection of the angle. Using simple trigonometry, the height can be determined [4].

Apart from its design, which appears to be purely geometric, the flap pedicle may benefit from the presence of perforators that would be included in the pattern [11].

This simple technique is quick to perform, reproducible, with low bleeding rates, and suitable for patients with significant comorbidities.

Our experience shows that neither vascular pedicle dissection nor fascia detachment is necessary, thus reducing the operative time and technicality of the procedure. The reliability of the flap is ideal, with a zero rate of total necrosis. The only case with partial necrosis, which later healed well with no sequelae, is consistent with other cases described [10]. For all cases, the hospital stay was less than 7 days.

The inclusion of local perforators in the flap design is unnecessary, but it may increase the reliability of the flap [10,11]. However, when the flap is well-traced, it becomes very reliable [4,6,18]. In our study, we did not consider including local perforators.

In our study, the aesthetic and functional outcomes were considered satisfactory.

5. Conclusion

The coverage of cutaneous LOS is a daily procedure for plastic surgeons. The V-Y advancement flap is a simple, useful, and reliable technique with low morbidity. This technique must be a part of surgeons' therapeutic arsenal and an option in cutaneous reconstruction.

Disclosure statement

The authors declare no conflict of interest.

Authors' contributions

The authors' participation was collegial in both writing and reviewing the manuscript. All authors have read and approved the final version of the manuscript.

References

- [1] Revol M, Servant JM, 2010, Suture, in *Surgical Techniques – Plastic, Reconstructive and Aesthetic Surgery*, Elsevier Masson SAS, Paris,45-030.
- [2] Revol M, Servant JM, 2010, Skin Grafts, in *Surgical Techniques – Plastic, Reconstructive and Aesthetic Surgery*, Elsevier Masson SAS, Paris, 45-070.
- [3] Andrades PR, Calderon W, Leniz P, et al., 2005, Geometric Analysis of the V-Y Advancement Flap and Its Clinical Applications. *Plast Reconstr Surg*, 115(6): 1582–1590.
- [4] Pauchot J, Servagi S, Laveaux C, et al., 2010, Coverage of a Dorsal Medial Loss of Substance by Two Latissimus Dorsi Rotation Musculocutaneous Flaps with V-Y Skin Paddle. Geometric Basis and Interest. A Case Report. *Annals of Aesthetic Plastic Surgery*, 55(1): 66–70.
- [5] Yildirim S, Taylan G, Akoz T, 2007, Freestyle Perforator-Based V-Y Advancement Flap for Reconstruction of Soft Tissue Defects at Various Anatomic Regions. *Ann Plast Surg*, 58(5): 501–506.
- [6] Binder JP, Servant JM, Revol M, 2014, Skin Flaps, in *Surgical Techniques – Plastic, Reconstructive and Aesthetic Surgery*, Elsevier Masson SAS, Paris, 45-080.
- [7] Binder JP, Revol M, 2012, Fasciocutaneous Flaps. *Surgical Techniques – Plastic, Reconstructive and Aesthetic Surgery*, Elsevier Masson SAS, Paris, 45-090.
- [8] Binder JP, Servant JM, Revol M, 2012, Perforating Flaps, in *Surgical Techniques – Plastic, Reconstructive and Aesthetic Surgery*, Elsevier Masson SAS, Paris, 45-096.
- [9] Conri V, Gaüzere R, Hocke C, et al., 2010, Study of a Series of Cutaneous-Fat Flaps Based on the Perforators of the Internal Pudendal Artery: Interest in Vulvar Reconstructive Surgery. *La Lettre du Gynécologue*, 2010(354).
- [10] Boucher F, Mojallal A, 2015, *Atlas of Perforating Arteries of the Skin, Trunk and Limbs*, Elsevier-Manson SAS, Paris.
- [11] Ennouhi MA, Kajout M, Moussaoui A, 2016, Interest of Medial Thigh Fasciocutaneous Flap in Fournier's Gangrene. *African Journal of Urology*, 22(4): 284–288.
- [12] Bonnet F, Paraskevas A, Petit F, et al., 2006, Use of Vacuum-Assisted Closure® for the Reconstruction of a Complex Loss of Substance of the Penis. *Ann Chir Plast Esthet*, 51(3): 249–252.
- [13] Lister GD, Gibson T, 1972, Closure of Rhomboid Skin Defects: The Flaps of Limberg and Dufourmentel. *Br J PlastSurg*, 25(3): 300–314.
- [14] Chu DY, 2003, Mathematical Principle of Planar Z-Plasty. *Plast Reconstr Surg*, 105(1): 105–108.

- [15] Behan FC, 2003, The Keystone Design Perforator Island Flap in Reconstructive Surgery. *ANZ J Surg*, 73(3): 112–120.
- [16] Rini IS, Gunardi AJ, Marsaulina RP, et al., 2020, A Systematic Review of the Keystone Design Perforator Island Flap in the Reconstruction of Trunk Defects. *Arch Plast Surg*, 47(6): 535–541.
- [17] Remache D, Chambert J, Pauchot J, et al., 2015, Numerical Analysis of the V-Y Shaped Advancement Flap. *Med Eng Phys*, 37(10): 987–994.
- [18] Haïdara TM, Amouzou KS, Hissein AH, et al., 2020, Iatrogenic Burns: About 2 Cases. *Health Sci Dis*, 24(6): 95–98.

Publisher's note

Bio-Byword Scientific Publishing remains neutral with regard to jurisdictional claims in published maps and institutional affiliations.