

High Uterosacral Ligament Suspension with Nonabsorbable Suture in Apical Prolapse: A 24-Month Follow-Up

Rodolfo E. Lopez-Orellana*, Francisco J. Kaplan-Delmar, Andres I. Yuivar-Santana, Tiare A. Hevia-Grez

Obstetrics and Gynecology Service, Pelvic Floor Unit, Quilpué Hospital, Viña del Mar, Chile

**Corresponding author:* Rodolfo E. López-Orellana, drlopezorellana@gmail.com

Copyright: © 2023 Author(s). This is an open-access article distributed under the terms of the Creative Commons Attribution License (CC BY 4.0), permitting distribution and reproduction in any medium, provided the original work is cited.

Abstract: *Background:* Pelvic organ prolapse (POP) is a common pathology affecting up to 60% of women. Transvaginal high uterosacral ligament suspension (HUSLS) is an alternative treatment for apical prolapse. HUSLS has short operative and recovery time, as well as low complication rate. *Objective:* To evaluate the objective and subjective success rates in patients with apical prolapse who underwent HUSLS at Quilpué Hospital over a 24-month follow-up. *Materials:* A retrospective, observational, descriptive study was carried out, and all symptomatic patients with apical prolapse \geq stage 2 POP-Q classification who underwent HUSLS between September 2014 and October 2019 were included in the study. Data were obtained from the database of the Urogynecology Unit of Quilpué Hospital, after approval by the ethics committee. Objective success was defined as C-point at 1 cm above the hymen, while subjective success was defined as “better” or “much better” in the Patient Global Impression of Improvement (PGI-I) scale and/or a visual analog scale (VAS) greater than 80% at 24 months of follow-up. *Results:* Of the 46 patients included in the study, the objective success rate was 84%, while the subjective success rate was 70%. *Conclusion:* Transvaginal HUSLS with permanent sutures is an excellent alternative treatment for apical prolapse, with a success rate similar to the gold standard at 24 months follow-up.

Keywords: Apical prolapse; High uterosacral ligament suspension

Online publication: May 15, 2023

1. Introduction

Pelvic organ prolapse (POP) is a common pathology that affects 40%–60% of women after one or more vaginal deliveries ^[1]. Before the age of 80, between 11% and 19% of women will undergo surgery to correct POP or urinary incontinence (UI) ^[2,3], thus demonstrating the epidemiological importance of this pathology. It is estimated that the demand for POP treatment in the next 30 years will increase by about 45% ^[4,5], given the sustained aging of the population. POP can affect the anterior and posterior vaginal wall as well as the uterus or vaginal vault in hysterectomized patients. The descent of the uterus or vaginal vault through the vagina is defined as an apical defect ^[6].

Both genetic and environmental factors contribute to the complex and multifactorial etiology of POP. Genetic factors can alter the resistance and elasticity of connective tissue, especially collagen, and the most common environmental factors known include pregnancy, vaginal delivery, forceps, age, birth weight, pelvic surgeries that affect the vascular and/or nerve supply, and diseases that chronically increase intraabdominal pressure ^[7,8].

The apical support of pelvic organs is conditioned by the integrity of the uterosacral-cardinal ligament complex and the vesicovaginal fascia, the rectovaginal fascia, and levator ani muscle (MEA) [9]. At present, surgery has been shown to be superior to conservative treatments for apical POP, and the gold standard, as of now, is uterine and/or vaginal sacropexy [1]. The native vaginal approach has demonstrated objective (anatomical) and subjective outcomes similar to those of the gold standard, with shorter operative and recovery times as well as lower complication rates and complexity [11].

At Quilpué Hospital, most apical prolapse are resolved vaginally by means of high uterosacral ligament suspension (HUSLS).

The aim of this study was to evaluate the anatomical and subjective success rates in patients with apical defect who underwent transvaginal HUSLS with nonabsorbable sutures over a follow-up period of 24 months. The secondary objective was to evaluate intraoperative and postoperative complications, anatomical success of the anterior and posterior compartment, operative time, and hospitalization time.

2. Materials and methods

A retrospective, observational, descriptive study was carried out between September 2014 and October 2019 at Quilpué Hospital, Chile. All patients older than 18 years who underwent HUSLS for symptomatic apical prolapse \geq stage 2 POP-Q classification were selected. Patients with previous POP surgery were excluded. The study design and protocol were approved by the ethics committee of the University of Valparaiso, Chile. Information was obtained from the database of the Urogynecology Unit and the operative protocol of the Surgical Unit of Quilpué Hospital.

Objective (anatomical) success was defined based on the location of the apical component (POP-Q point C 1 cm above the hymen) and the anterior and/or posterior vaginal wall (POP-Q point Aa, Ba, Ap, or Bp above 0). Subjective success was defined as “better” or “much better” in Patient Global Impression of Improvement (PGI-I) scale and/or a visual analogue scale (VAS) greater than 80% for POP symptoms [13]. Transvaginal HUSLS was performed based on Shull’s technique, identifying both uterosacral ligaments at the level of the ischial spines, mounting one or two polypropylene sutures on each of them, and then anchoring them to the vesicovaginal and rectovaginal fasciae at the level of the vaginal vault, after a classic vaginal hysterectomy. In required cases, vaginoplasty of the anterior or posterior wall was performed, plicating the respective fascia with polydioxanone sutures and perineoplasty on a case-by-case basis as well as TVT (tension-free vaginal tape) or TOT (transvaginal obturator tape) in patients with stress urinary incontinence (SUI). Closure of the vaginal vault was performed with polyglycolic acid sutures, leaving the polypropylene sutures of the HUSLS completely covered. In all cases, ureteral patency was assessed with intraoperative cystoscopy and intravenous Indigo Carmine®. One or two vaginal gauzes were left in place for 24 hours. Postoperative controls were performed at 3, 6, 12, and 24 months.

Statistical analysis was performed with Stata, a statistical software for data science. The baseline demographic and clinical variables were expressed in mean and standard deviation, and the statistical analysis was descriptive. Kaplan-Meier curves were used to analyze the anatomical and subjective success rates over time.

3. Results

Fifty-six patients underwent surgery, among which seven (10%) did not present themselves for postoperative follow-up, and three (4%) did not have complete data, so only 46 patients were included in the study (**Figure 1**). The average age was 66 years old, average parity was 3.5, and average body mass index (BMI) was 28.4 kg/m² (**Table 1**).

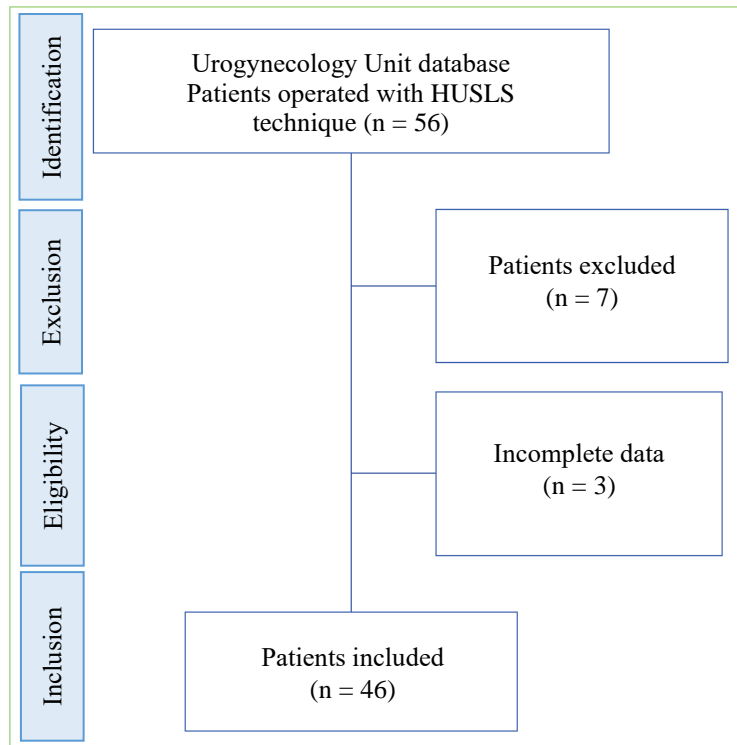


Figure 1. Patient selection process

Table 1. Baseline demographic variables

Demographic variables	Average (mean \pm standard deviation, SD)
Age	66.39 \pm 8.02
Number of births	3.5 \pm 1.81
Body mass index	28.4 \pm 4.42

As shown in **Table 2**, the most frequent comorbidity was arterial hypertension (AHT), with a proportion of 43.5%; with regard to the affected compartment, all had apical defect, 54% had anterior compartment defect, and 11% had posterior compartment defect. The same figure shows that 82.6% of the patients had \geq stage 3 prolapse.

Table 2. Baseline clinical variables

Baseline clinical characteristics	n (%)
Previous POP surgeries	2 (4.35%)
POP-Q \geq 2	46 (100%)
POP-Q \geq 3	38 (82.6%)
Arterial hypertension	20 (43.5%)
Diabetes mellitus	5 (10.9%)
SUI	25 (54%)
Affected compartment	
Apical	46 (100%)
Anterior	25 (54%)
Posterior	5 (11%)

Abbreviations: POP: pelvic organ prolapse; SUI, stress urinary incontinence.

All patients underwent intraoperative cystoscopy with Indigo Carmine® to evaluate ureteral patency, 67% underwent salpingectomy, 54% underwent surgery for SUI, and 67% underwent vaginoplasty (anterior, posterior, and/or perineoplasty), with anterior vaginoplasty being the most frequent. The average operative time and hospitalization time were 103 minutes and 2.2 days, respectively (**Table 3**).

Table 3. Average operative time and hospitalization time

Hospitalization time (days)	2.2 ± 0.59
Operative time (minutes)	103 ± 19
Intraoperative complications	2.1%
Suture exposure	15%
Conversion to abdominal surgery	0%

The objective and subjective success rates in patients with apical defect were 96% (95% confidence interval [CI]: 0.74–0.79) and 93% (95% CI: 0.75–0.98) at 12 months follow-up, respectively, and 84% (95% CI: 0.43–0.96) and 70% (95% CI: 0.32–0.89) at 24 months follow-up, respectively. Both are expressed in Kaplan-Meier survival curves (**Figure 2**).

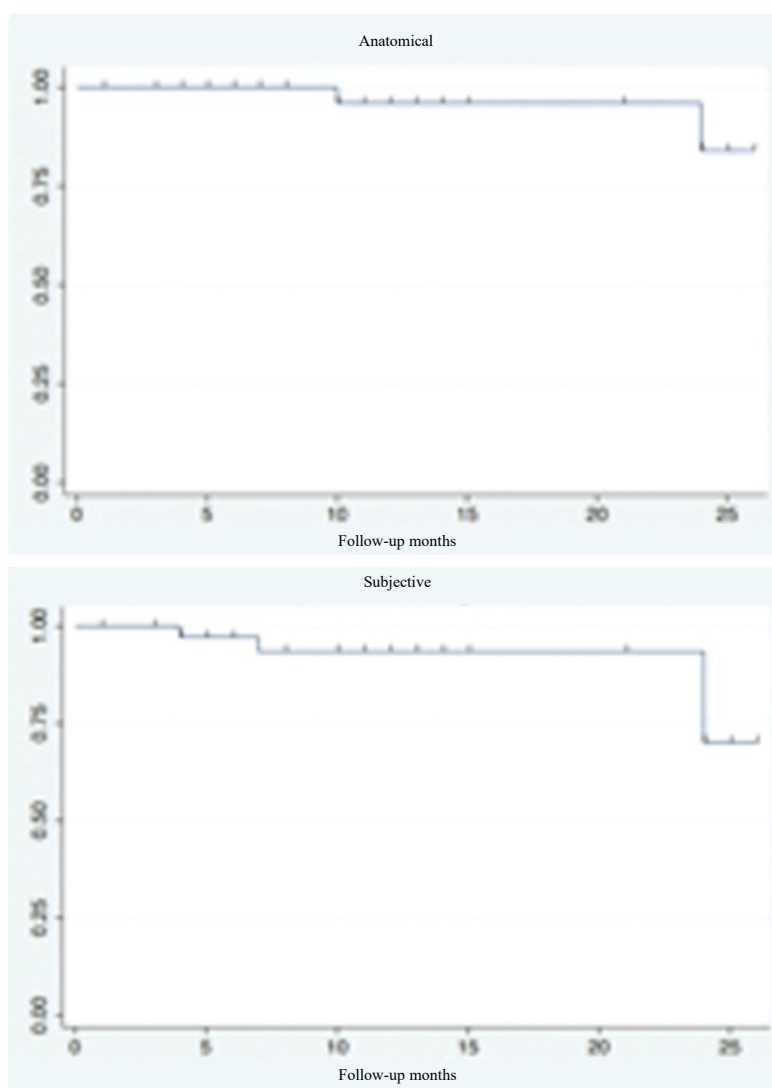


Figure 2. Kaplan-Meier survival curves of anatomical and subjective success rates in patients

The follow-up at 6, 12, and 24 months is detailed in **Table 4**.

Table 4. Follow-up at 6, 12, and 24 months

Follow-up	6 months	12 months	24 months
n (%)	28 (61%)	23 (50%)	12 (26%)

Seven patients (15%) had anterior compartment failure, of which 2 were at six months, 2 at 12 months, and 3 at 24 months postoperative follow-up. Two patients (4%) had posterior compartment failure, with only one requiring corrective surgery.

As shown in **Table 3**, only 1 patient (2.1%) had intraoperative complications. The complication was the failure to prove right ureteral patency with Indigo Carmine®. In 7 patients (15%), there was evidence of exposure of Prolene® suture in the vaginal vault during the postoperative follow-up period.

4. Discussion

Currently there are several surgical approaches to apical prolapse, of which the gold standard is uterine and/or vaginal sacropexy. However, the vaginal approach has been proven to be an excellent alternative. Our results are similar to those of Nygaard in the 2013 CARE study and those of Rondini in 2015. We believe that the use of nonabsorbable sutures and the surgical technique itself contributes to the rationale. It is important to emphasize that 82.6% of patients in our study presented with advanced POP, (\geq stage 3) and despite this, we achieved good anatomical and subjective results.

Of the cases who had recurrent apical prolapse, one was resolved surgically by bilateral sacrospinous ligament fixation, while another by colpocleisis, since the patient is not sexually active.

We believe that the low percentage of intraoperative and postoperative complications was due to the small sample size and the fact that the surgeries were performed by a single surgeon with strict and formal training in urogynecology. Only one patient had intraoperative complication; right ureteral patency could not be proven with Indigo Carmine® or by means of catheterization even after 40 min of cystoscopic observation, so the right suture was removed; subsequently, we verified that the patient had chronic renal disease with a significant decrease in renal function, thus explaining the delay in Indigo Carmine® depuration; however, despite the fact that only the left suture was maintained, the patient had no treatment failures during the 24 months of follow-up.

Only 7 (15%) patients had Prolene® suture exposure in the vaginal vault at 24 months of follow-up, and most of them were asymptomatic. Only 5 patients presented with dyspareunia. All exposures were resolved by cutting the suture in the outpatient clinic; this completely eliminated the symptoms.

Our study showed that HUSLS has shorter operative time than colposacropexy, despite the fact that several surgeries were associated with it, including -plasty of other compartments, treatment for SUI, and salpingectomy, which may further lengthen the operative time^[14,15]. The decision to perform salpingectomy is related to the prevention of ovarian epithelial carcinoma^[16].

The current gold standard for apical prolapse is still colposacropexy, which has been shown to have higher anatomical success rates than other techniques; although it has similar subjective success rates to HUSLS, it has significantly longer operative time^[11,15], more severe complications^[17], longer hospitalization time^[11], longer learning curve, and higher costs^[14,18] compared to HUSLS. This leads us to believe that HUSLS is an excellent alternative treatment for apical prolapse, given that the patient's perception of improvement (subjective) is more important than that of the physician (objective).

The strengths of this study are as follows: all surgeries were performed by the same surgeon with a standardized technique; all patients were thoroughly evaluated before and after surgery; and all data were

tabulated in the patient management file under the Urogynecology Unit of Quilpué Hospital.

Among the limitations of the study, we would like to emphasize the retrospective nature of the study, the size of the sample, and the proportion of patients who remained under follow-up up to 24 months after surgery, although we believe that if there had been more symptomatic recurrences, a greater proportion of patients would have continued to follow-up. Another potential limitation is that the postoperative evaluation was done by the same surgeon who performed the surgery, which may lead to bias. With respect to subjective success, the drop from 93% to 70% could be due to the sum of objective failures (POP-Q > 0) that lead to symptoms such as vulvar lumpiness and those caused by concomitant pathologies such as polyuria due to decompensated diabetes, urine incontinence, and/or lack of estrogen since it may be difficult for some patients to differentiate the symptoms of POP from those of other anatomically close pathologies. It should be noted that the majority of patients who underwent surgery had more than one pathology.

5. Conclusion

HUSLS with nonabsorbable sutures is an excellent alternative for treating apical prolapse vaginally, with a high rate of anatomical and subjective success, improvement in the quality of life of patients, and a low rate of complications (less than 5%), in addition to shorter operative time and hospital stay. More statistically studies are required to confirm these findings.

Disclosure statement

The authors declare no conflict of interest.

Data availability

The supplementary material of this work is available at <https://doi.org/10.24875/RECHOG.22000005>. The content of the supplementary material is the sole responsibility of the authors.

References

- [1] Jelovsek JE, 2020, Pelvic Organ Prolapse in Women Choosing a Primary Surgical Procedure, UpToDate, viewed in 2020, <https://www.uptodate.com/contents/pelvic-organ-prolapse-in-women-choosing-a-primary-surgical-procedure>
- [2] Olsen AL, Smith VJ, Bergstrom JO, et al., 1997, Epidemiology of Surgery Managed Pelvic Organ Prolapse and Urinary Incontinence. *Obstet Gynecol*, 89: 501–506.
- [3] Løwenstein E, Ottesen B, Gimbel H, 2015, Incidence and Lifetime Risk of Pelvic Organ Prolapse Surgery in Denmark from 1977 to 2009. *Int Urogynecol J*, 26: 49–55.
- [4] Boyles SH, Weber AM, Meyn L, 2003, Procedures for Pelvic Organ Prolapse in the United States 1979–1997. *Am J Obstet Gynecol*, 189: 70–75.
- [5] Lubner KM, Boero S, Choe JY, 2001, The Demographics of Pelvic Floor Disorders: Current Observations and Future Projections. *Am J Obstet Gynecol*, 189: 1496–1501.
- [6] The American College of Obstetrics and Gynecologists, 2019, Pelvic Organ Prolapse. *Female Pelvic Med Reconstr Surg*, 25(6): 397–408.
- [7] Maher C, Feiner B, Baessler K, et al., 2013, Tratamiento Quirúrgico del Prolapso de Órganos Pélvicos en Mujeres [Surgical Treatment of Pelvic Organ Prolapse in Women]. *Cochrane Database Syst Rev*, 2013(4): CD004014.

- [8] Moalli PA, Ivy SJ, Meyn LA, et al., 2003, Risk Factors Associated with Pelvic Floor Disorders in Women Undergoing Surgical Repair. *Obstet Gynecol*, 101: 869–874.
- [9] DeLancey JO, 1992, Anatomic Aspects of Vaginal Eversion After Hysterectomy. *Am J Obstet Gynecol*, 166: 1717–1724.
- [10] Shull BL, Bachofen C, Coates KW, et al., 2000, A Transvaginal Approach to Repair of Apical and Other Associated Sites of Pelvic Organ Prolapse with Uterosacral Ligaments. *Am J Obstet Gynecol*, 183: 1365–1373.
- [11] Rondini C, Braun H, Alvarez J, et al., 2015, High Uterosacral Vault Suspension Vs Sacrocolpopexy for Treating Apical Defects: A Randomized Controlled Trial with Twelve Months Follow-Up. *Int Urogynecol J*, 26(8): 1131–1138.
- [12] Busquets M, Castillo F, 2009, Uso del Sistema POPQ para la Clasificación Delos Prolapsos: Hospital Parroquial de San Bernardo [Use of the POPQ system for prolapses classification: Hospital Parroquial de San Bernardo. *Rev Chil Obstet Ginecol*, 74(1): 4–10.
- [13] Meister MR, Sutcliffe S, Lowder JL, 2017, Definitions of Apical Vaginal Supportless: A Systematic Review. *Am J Obstet Gynecol*, 216(3): 232.e1–232.e14.
- [14] Alas AN, Anger JT, 2015, Management of Apical Pelvic Organ Prolapse. *Curr Urol Rep*, 16(5): 33.
- [15] Maher C, Feiner B, Baessler K, et al., 2016, Surgery for Women with Apical Vaginal Prolapse. *Cochrane Database Syst Rev*, 10(10): CD012376.
- [16] Yoon SH, Kim SN, Shim SH, et al., 2016, Bilateral Salpingectomy Can Reduce the Risk of Ovarian Cancer in the General Population: A Meta-Analysis. *Eur J Cancer*, 55: 38–46.
- [17] Diwadkar GB, Barber MD, Feiner B, et al., 2009, Complication and Reoperation Rates After Apical Vaginal Prolapse Surgical Repair: A Systematic Review. *Obstet Gynecol*, 113: 367–73.
- [18] Cheon C, Maher C, 2013, Economics of Pelvic Organ Prolapse Surgery. *Int Urogynecol J*, 24(11): 1873–1876.

Publisher's note

Bio-Byword Scientific Publishing remains neutral with regard to jurisdictional claims in published maps and institutional affiliations.